
KING'S
College
LONDON



Preventing and managing neuropathic pain



Faculty of Dentistry, Oral & Craniofacial Sciences

Tara.renton@kcl.ac.uk

Professor Oral Surgery Kings College London Past President British Association of Oral Surgeons

KING'S
College
LONDON

Objectives

- ▶ The attending delegates will:
 - ▶ - Understand the impact of nerve injuries on patients affected;
 - ▶ - Be familiar in minimising risk of nerve injury when undertaking dental procedures;
 - ▶ - Be familiar in risk assessment for identifying patients at higher risk
 - ▶ - Know when to refer or treat.



Trigeminalnerve.org.uk

TRIGEMINAL FOUNDATION

Nerve Injuries

Helping to prevent, educate and manage



Search



[Home](#)
[About us](#)
[Patient](#)
[Professional](#)
[Education](#)

[Research](#)
[Events](#)
[Referrals ^{urgent}](#)
[Get-involved](#)
[Contact](#)

[Register / login](#)

[CPD Questions](#)

[TNI Blog / Forum](#)

[Direct Email](#)

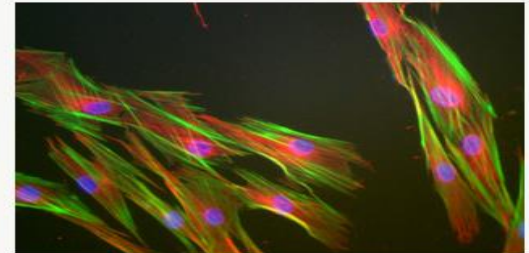


Survey to gather interest in a new MSc course in o...
[find out more...](#)



Is your injury related to:

- [Wisdom tooth](#) →
- [Implant related](#) →
- [Dental injection](#) →
- [Root canal](#) →



Free CPD sign up here

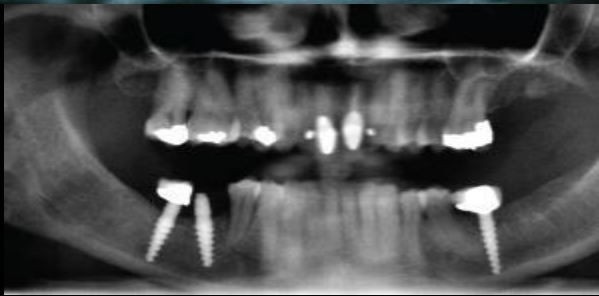
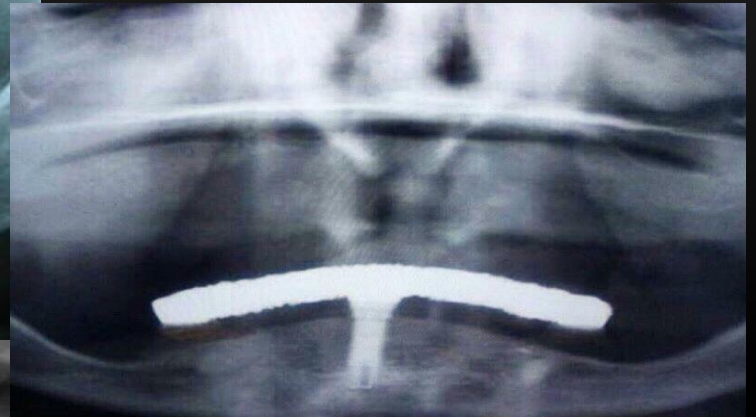
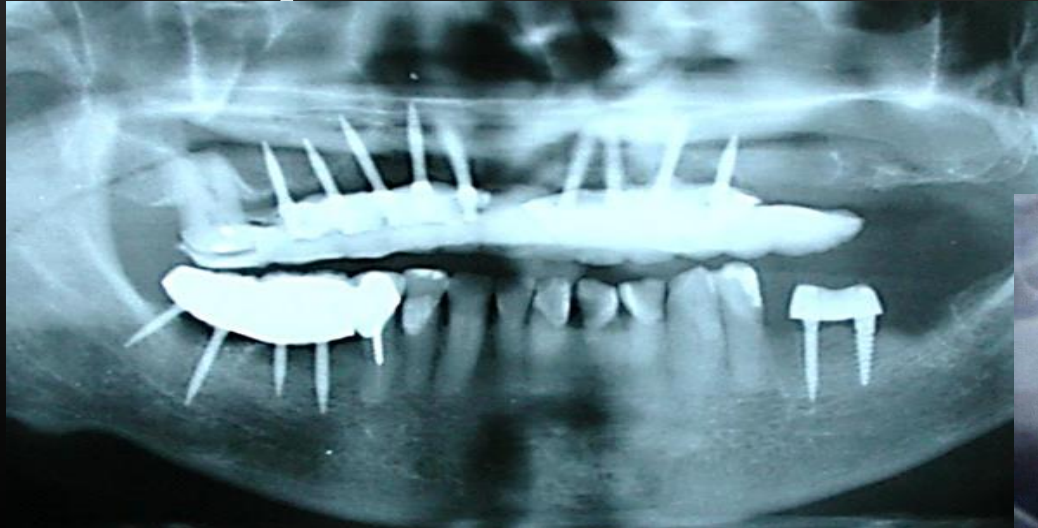
Continuing Professional Development – TNI provides structured and comprehensive range of evidence-based educational activities to challenge and stimulate practitioners, specialists, consultants and all members...



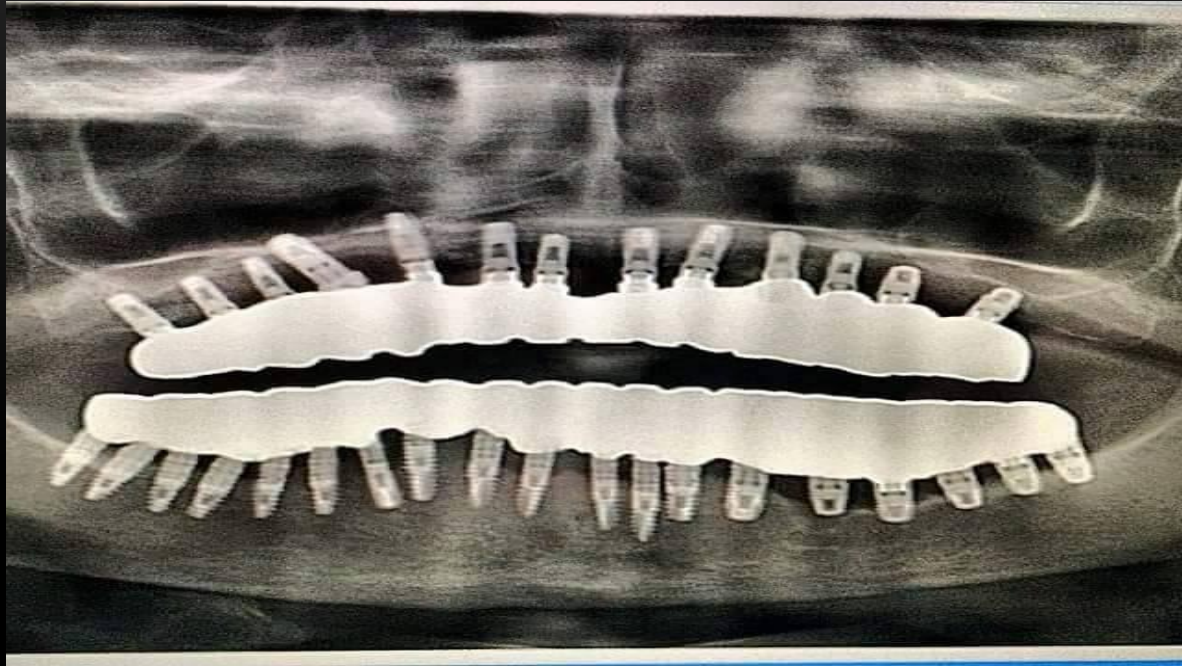▶ There are three kinds of dental surgeons.....



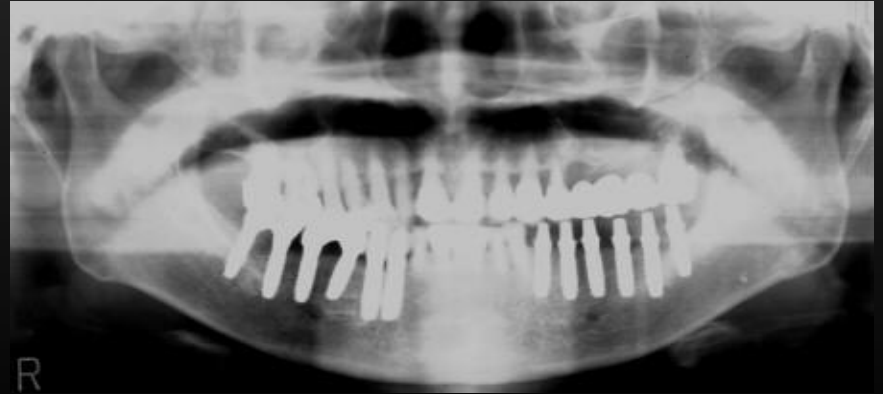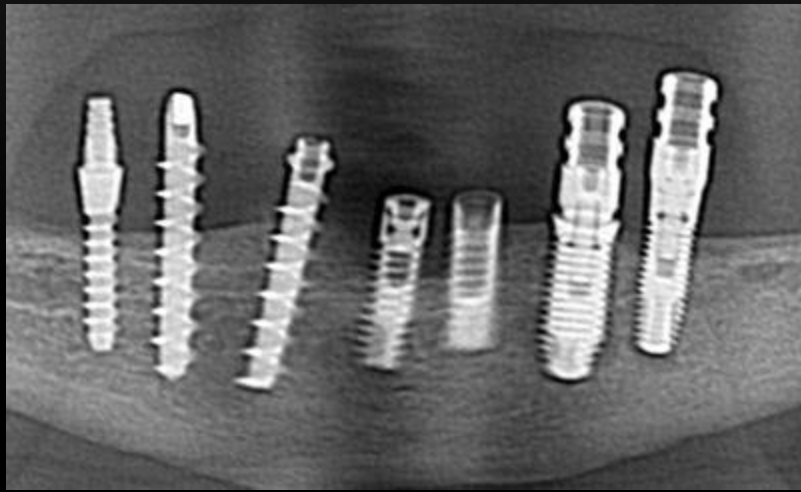
The Optimists



The Pessimists

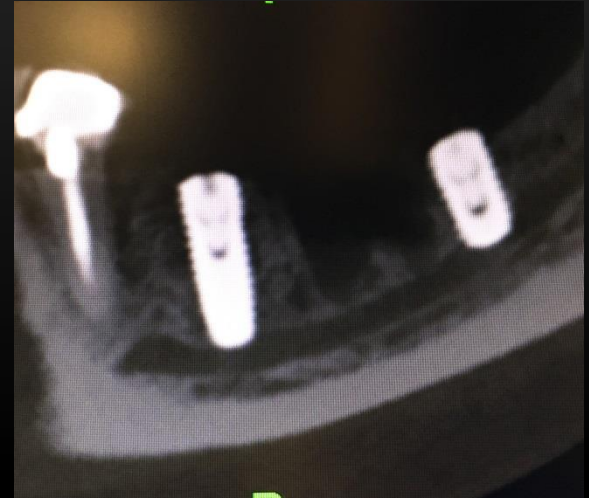


And the undecided.....

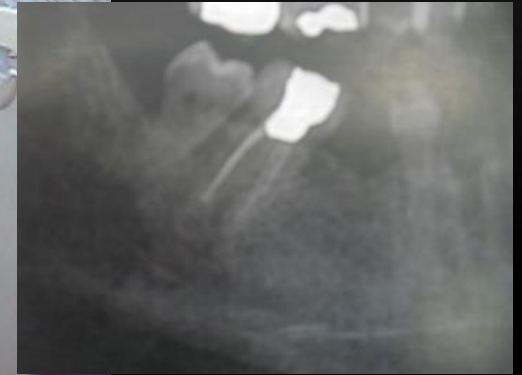


However.....


- ▶ All dentists are optimists when considering the outcome of nerve injuries in their own patients!




Late diagnosis of Endo PTN causing additional morbidity




Overview



Why prevent these injuries?




How to prevent these injuries?




How to manage these injuries?




Overview



Why prevent these injuries?



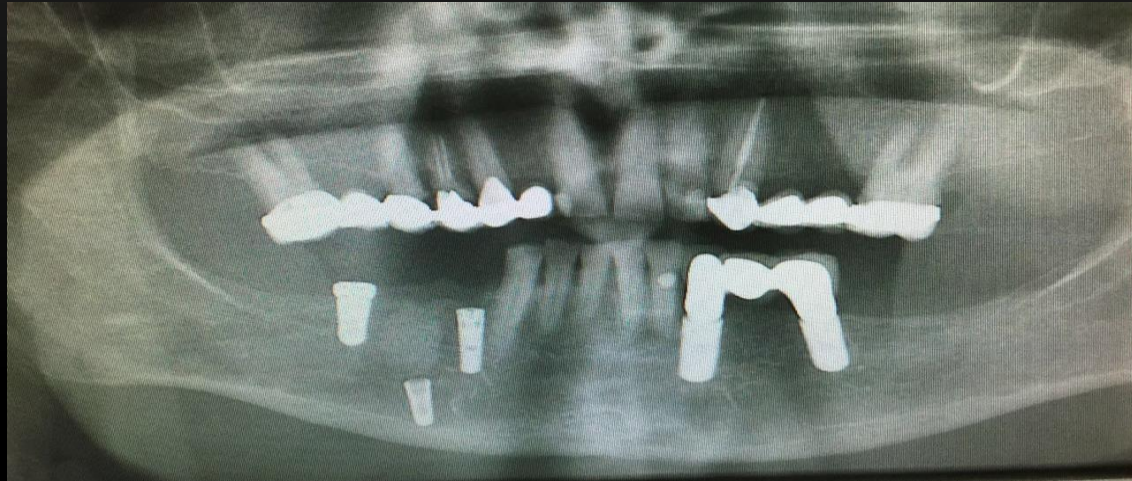
How to prevent these injuries?



How to manage these injuries?

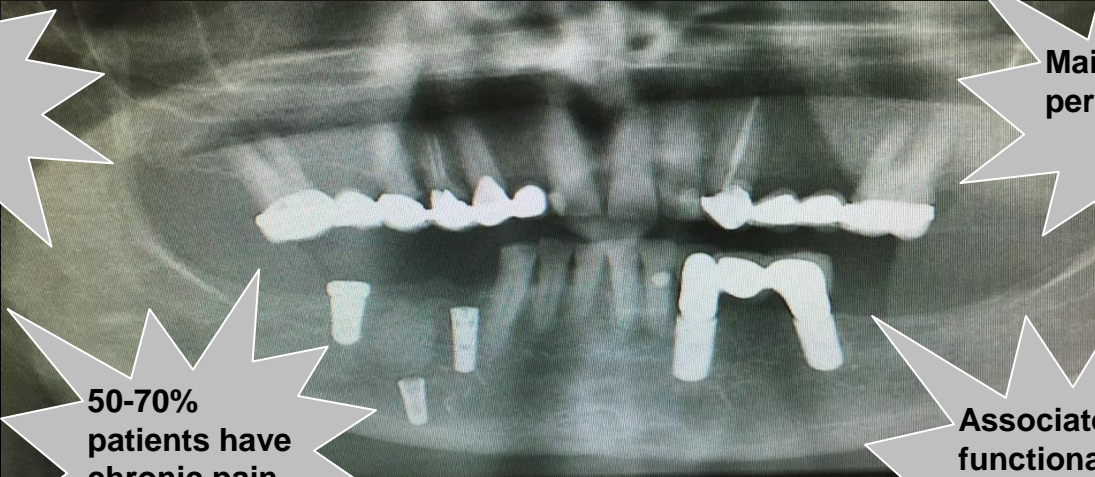


Why are nerve injuries such a big deal ?



Why are nerve injuries such a big deal ?

**Avoidable /
negligent**



**Mainly
permanent**

**50-70%
patients have
chronic pain**

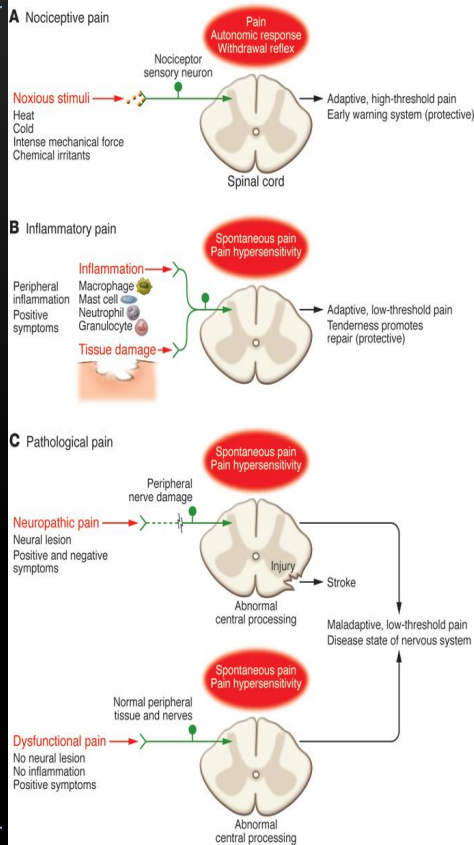
**Associated
functional and
psychological
impact**



The consequences of trigeminal nerve injury include;

- ▶ Constant pain, numbness and altered sensation
 - ▶ (>70% of patients, 95% implant /endo related nerve injuries)
- ▶ Permanent nerve injury after implants
 - ▶ (92%, endo 95%, LA 25%)
- ▶ Functional problems with speech, socialising and coping with pain (all patients)
- ▶ Psychological impact
 - ▶ (68% of patients have Post traumatic stress disorder)
- ▶ Medicolegal issues
- ▶ **Nerve trauma caused by dental implant placement is associated with altered sensation and chronic pain.** Complete or partial loss of sensation is often reported by patients who have experienced nerve trauma during implant surgery. Some patients report persistent pain and neurosurgery disturbance long after the normal healing time has passed. In addition, neuropathic pain is reported after implant surgery.
- ▶ **Practitioners who place dental implants must be familiar with the differential diagnosis, prevention, and management of neuropathic pain.**

Types of pain



Healthy acute pain

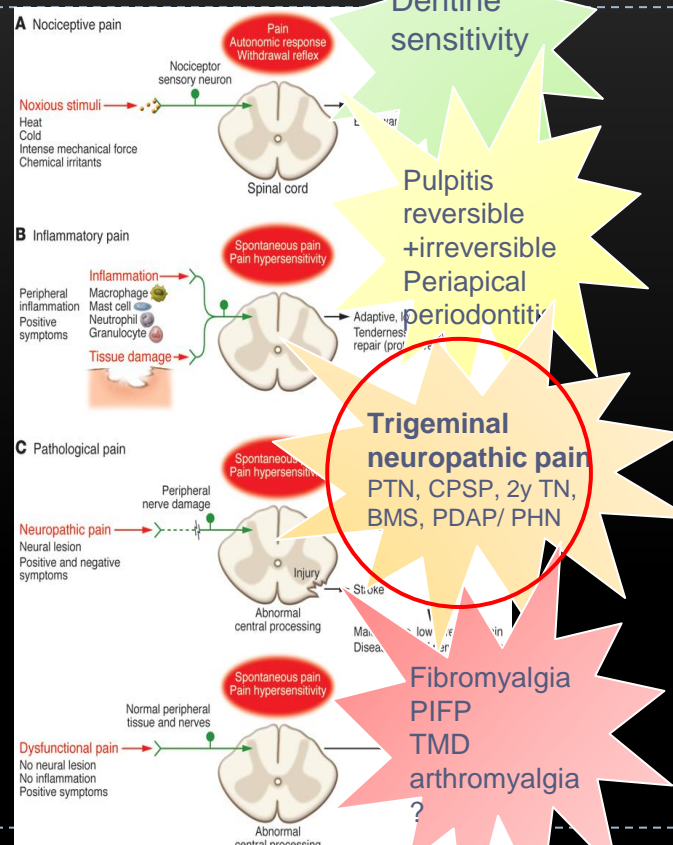
Nociceptive
healthy feeling pain 'pain'

Inflammatory pain
healthy short lived after insult

Chronic pain =
disease of neuromatrix

Neuropathic pain
Associated with nerve lesion

Dysfunctional or centralised pain
Unknown cause



Dentine sensitivity

Pulpitis
reversible
+irreversible
Periapical
periodontitis

Trigeminal
neuropathic pain
PTN, CPSP, 2y TN,
BMS, PDAP/ PHN

Fibromyalgia
PIFP
TMD
arthromyalgia
?

Chronic post surgical pain

Kehlet H *et al*, 2006 *Lancet*

	Estimated incidence of chronic pain	Estimated chronic severe (disabling) pain (>5 out of score of 10)	US surgical volumes (1000s)†
Amputation ²	30–50%	5–10%	159 (lower limb only)
Breast surgery (lumpectomy and mastectomy) ³	20–30%	5–10%	479
Thoracotomy ^{4,7}	30–40%	10%	Unknown
Inguinal hernia repair ⁸⁻¹⁰	10%	2–4%	609
Coronary artery bypass surgery ¹¹⁻¹³	30–50%	5–10%	598
Caesarean section ¹⁴	10%	4%	220

* Gall bladder surgery not included, since preoperative diagnosis of pain specifically from gall bladder is difficult and persistent postoperative pain could therefore be related to other intra-abdominal disorders. †National Center For Health Statistics, Ambulatory and Inpatients Procedures, USA, 1996.

Table 1: Estimated incidence of chronic postoperative pain and disability after selected surgical procedures*

30% get persistent pain 10% are severely affected
Very few related to dentistry likely due to LA

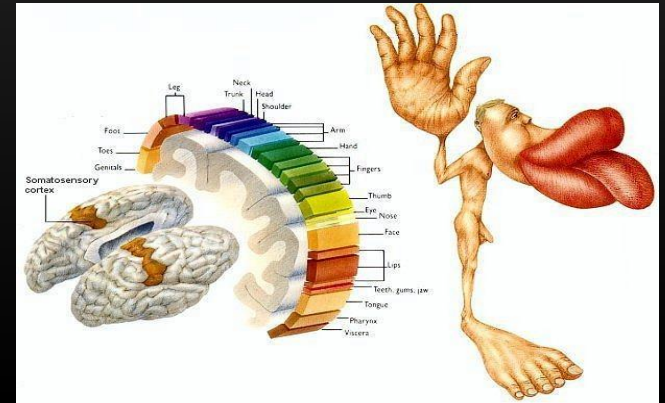
Patient risk factors for chronic post surgical pain

- ▶ Age -Higher risk of persistent neuropathy over 50 years
- ▶ Pre-existing NePain conditions Migraine, Fibro Myalgia
- ▶ Pre-existing nerve pathology
- ▶ Psychological diagnoses (cognitive fear pain and or surgery, personality disorder poor coping, hypervigilance, catastrophising, introversion)
- ▶ Prior abuse and neglect or institutionalisation or significant life event

- ▶ Minimising CPSP
 - ▶ minimal access surgery
 - ▶ Local anaesthesia
 - ▶ Good perioperative pain management

Particular issues with Trigeminal pain?

- ▶ Big part of our lives
- ▶ Underpins the primordial survival instincts
- ▶ Constant unavoidable activity
- ▶ Underpins daily pleasure in health
 - ▶ Eating
 - ▶ Drinking
 - ▶ Speaking
 - ▶ Smiling
 - ▶ Sexual interaction

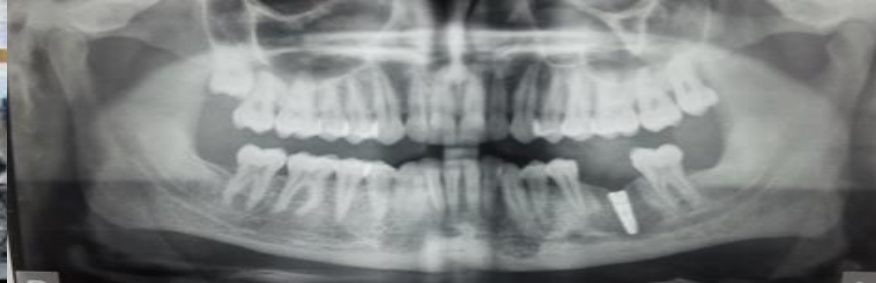

- ▶ **Underpins our identity!**

Most nerve injuries are permanent and cannot be fixed



Consequences of V nerve injury for the patient



Consequences of nerve injury

Pathophysiological

- ▶ The IAN is contained within a bony canal which predisposes it to compression and possible ischaemic type injury. **Compression of peripheral sensory nerves over 6 hours can evoke nerve fibre atrophy**
- ▶ Shimp T, Gilliatt RW, Kennett RP, Allen PJ. Susceptibility to pressure neuropathy distal to a constricting ligature in the guinea-pig. J Neurol Neurosurg Psychiatry. 1987 Dec;50(12):1625-32
- ▶ **Ischaemia alone without direct nerve damage will cause sufficient neural inflammation and damage to cause permanent nerve injury.**
- ▶ Park YT, Kim SG, Moon SY. Indirect compressive injury to the inferior alveolar nerve caused by dental implant placement. J Oral Maxillofac Surg. 2012 Apr;70(4):e258-9.
- ▶ **Three months after the IAN injury, permanent central and peripheral changes** occur within the nervous system subsequent to injury, that are unlikely to respond to surgical treatment intervention

Clinical presentation

Trigeminal Post Traumatic Neuropathy (n=525)

- ▶ **Onset of neuropathy +/- pain correlates with intervention surgery or local anaesthetic**
 - ▶ LNI patients (mean age 38.4 years [range 20-64]
Male:Female ratio 37:63%
 - ▶ IANI patients (mean age 43.2 years [range 22-85];
Male:Female ratio 27:70%
- ▶ Referral from:
 - ▶ General dental practitioner LNI = 40%/IANI = 51%
 - ▶ Specialist LNI = 50% IANI = 32%
- ▶ **Reported extreme pain during surgery 48%**
- ▶ **Reported high level pain post surgically 56%**

- ▶ IANI related to;
 - ▶ Third molar surgery 60%
 - ▶ Implant 14%
 - ▶ LA 16%
 - ▶ Endo 8%
- ▶ Periapical infections 1%
- ▶ Facial electrolysis 1%



Pain descriptors

Presenting with neuropathic pain 70%

Functionality

Significantly daily functional impact 65%

Increased with associated pain

Psychologically (PTSD in 68% of patients)

Significant impact especially with pain 62%

Neuropathy 100%

Dermatome: The neuropathic area varied between 5-100% of the affected dermatome (intra- and/or extra-orally).

Hypoeesthetic or Hyperaesthetic?

Mechanical allodynia 70%

Mechanical Hyperalgesia 48%

CBT			
	Neuropathic Area (%)	Subjective Function	
		Min	Max
Extraorally	70 (2-100)	3.1 (0-10)	8.8 (1-30)
Intraorally	66 (0-100)	2.3 (0-5)	10.5 (6-12)
Versatis			
	Neuropathic Area (%)	Subjective Function	
		Min	Max
Extraorally	68 (8-100)	1.75 (1-2)	9.6 (4-12)
Intraorally	69 (0-100)	4.0 (4)	10.0 (6-12)

Consequences

Presentation Features of neuropathic pain

Pain

Allodynia pain with non noxious stimulus

pain on touch/cold/hot

- 70% mechanical allodynia
- Cold allodynia a particular feature of extra oral dermatome in patients with IANIs
- Some LNI patients report tastent and warm allodynia

Hyperpathia pain continues when stimulus removed
54% patients

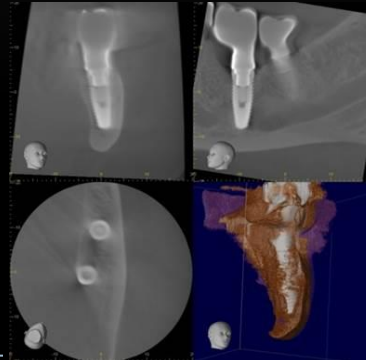
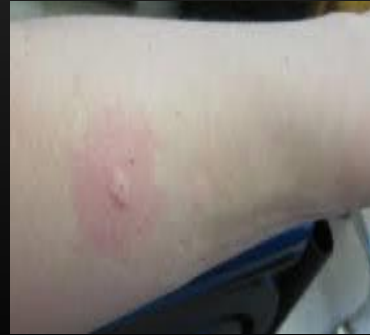Hyperalgesia increased pain to painful stimulus **48% of patients**

Altered sensation -Hyperaesthesia

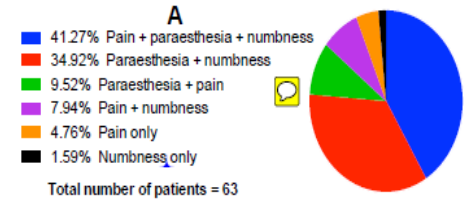
- Paraesthesia –pins and needles, formication, many descriptions
- Dysaesthesia – uncomfortable sensations often burning

Anaesthesia -Numbness- **hypo aesthesia**

Wheal and flare



Neuropathic pain in 60 patients post implant nerve injury



Neuropathic pain in;
95% of implant patients
92% of endodontic nerve injuries
57% of wisdom tooth surgery
IANI > LNI



Consequences of nerve injury

Permanent chronic pain.....10 years on

Consent re nerve injury

- Less than 24% of implants patients
- No LA or endo nerve injury patients were warned
- 90% of M3M patients
- Only 10% of M3M patients were advised of high risk



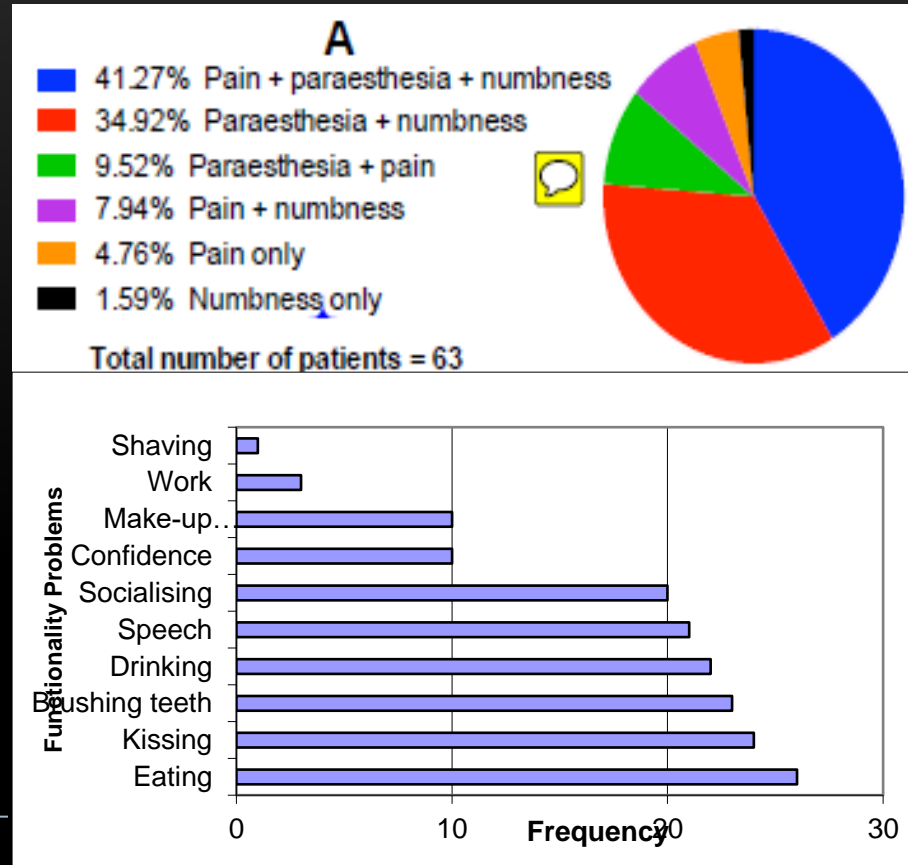
Renton T, Dawood A, Shah A, Searson L, Yilmaz Z. Post-implant neuropathy of the trigeminal nerve. A case series. Br Dent J. 2012 Jun 8;212(11):E17. doi: 10.1038/sj.bdj.2012.497, Ucer C, **Yilmaz Z**, Scher E, Suzuki J, **Renton T**. A Survey of the Opinion and Experience of UK Dentists Part 3: An Evidence-Based Protocol of Surgical Risk Management Strategies in the Mandible. Implant Dent. 2017 May 10. doi: 10.1097/ID.0000000000000602. [Epub ahead of print] **Yilmaz Z**, Ucer C, Scher E, Suzuki J, **Renton T**. A Survey of the Opinion and Experience of UK Dentists: Part 2: Risk Assessment Strategies and the Management of Iatrogenic Trigeminal Nerve Injuries Related to Dental Implant Surgery. Implant Dent. 2017 Apr;26(2):256-262. **Yilmaz Z**, Ucer C, Scher E, Suzuki J, **Renton T**. A Survey of the Opinion and Experience of UK Dentists: Part 2: Risk Assessment Strategies and the Management of Iatrogenic Trigeminal Nerve Injuries Related to Dental Implant Surgery. Implant Dent. 2016 Oct;25(5):638-45

Consequences

Neuropathy causing functional problems

Recent study @ KCL on 100 implant
nerve injury patients
**95% of implant nerve injury
neuropathic pain**
92% permanent
Functional and psychological impact

Renton T, Dawood A, Shah A, Searson L, Yilmaz Z. Post-
implant neuropathy of the trigeminal nerve. A case series. Br Dent
J. 2012 Jun 8;212(11):E17. doi: 10.1038/sj.bdj.2012.497

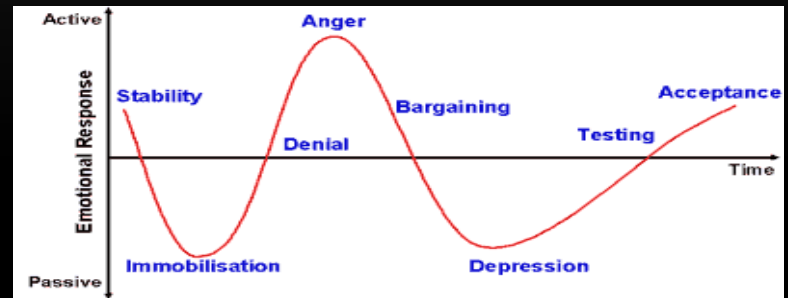


Psychological consequences

- ▶ Depression
- ▶ Anger
- ▶ Post traumatic stress disorder 68%
- ▶ Victim of abuse
- ▶ Loss of ability to trust



Kubler Ross

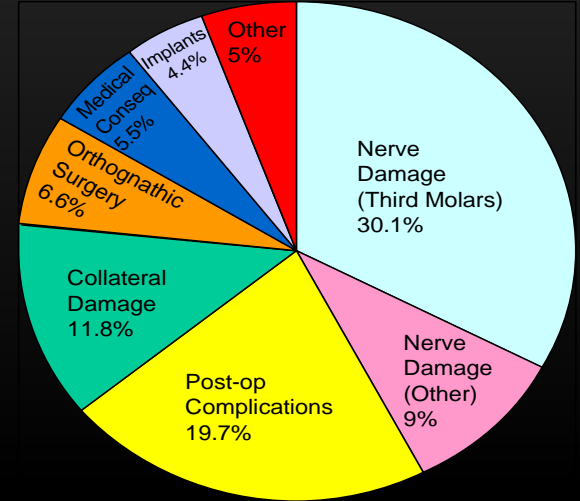


The psychosocial and affective burden of posttraumatic neuropathy following injuries to the trigeminal nerve. **Smith JG, Elias LA, Yilmaz Z, Barker S, Shah K, Shah S, Renton T.** J Orofac Pain. 2013 Fall;27(4):293-303. doi: 10.11607/jop.105 Sullivan MJ et al. Catastrophizing and perceived injustice: risk factors for the transition to chronicity after whiplash injury. Spine (Phila Pa 1976). 2011 Dec 1;36(25-Suppl):S244-9 Dec;92(12):2041-56. Review

Medicolegal consequences

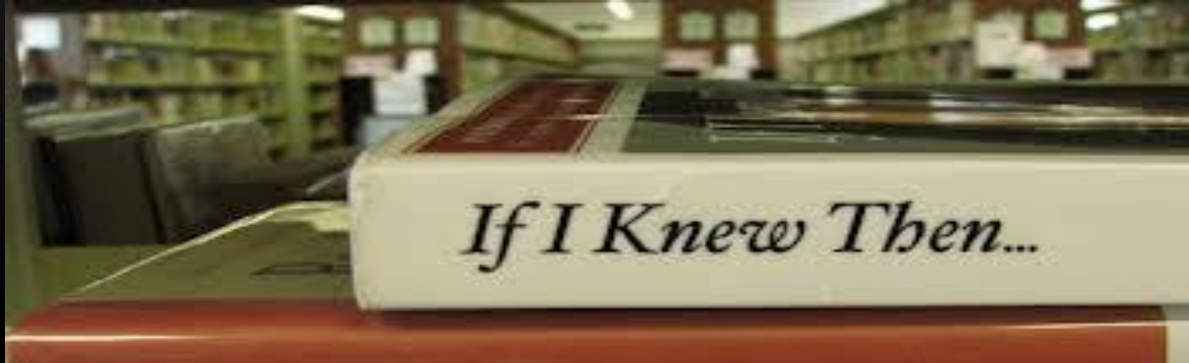Nerve damage related to dental procedures are often **NEGLIGENT** as they are elective surgery and damage is avoidable.

- ▶ This results in litigation and Settlements getting more expensive
 - ▶ Implant related cases settlements \$1-3 million (2011)



Patient's perspective

When the damage is done



Its too late!



Pains of the trigeminal system

Inflammatory pain

Toothache

Abscess

TMD arthritides,
Trauma, Sialadenitis,
Sinusitis, mucosal
disease

Nociceptive pain

Dentine
sensitivity

Secondary Neuropathic

Causes MS DM

Trigeminal
neuralgia (IX, VII)

**PPTTN = PDAP
II)**

Autonomic

Neurovascular

Primary & Secondary
Headaches

Trigeminal Autonomic
Cephalalgias (TACs)

Giant cell arteritis

Primary Neuropathic

Neuropathic
dental pain
(PDAPI)

TN idiopathic

**Burning
Mouth**

TMDs

Dysfunctional
Arthritides
Myofacial

Dysfunctional pain


Associated multiple
pain conditions
LBP IBS FM

Referred pain


Heart
Cervical
Lung

CANCER


Overview



Why prevent these injuries?



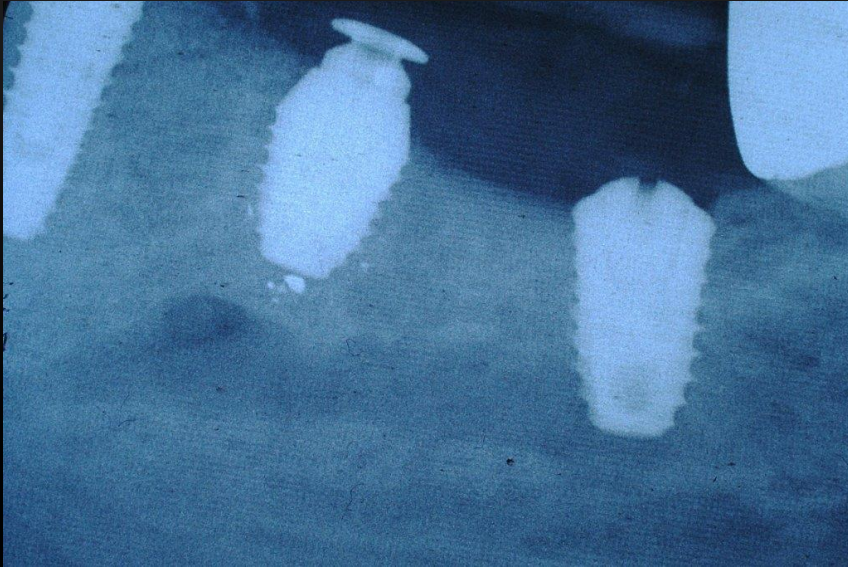
How to prevent these injuries?



How to manage these injuries?



Preventing dentistry related nerve injury



How do we prevent these injuries?

- ▶ Managing patients expectations
- ▶ Risk assessment and management
- ▶ Operative technique
- ▶ Post op follow up
- ▶ Recognition and early medical and or surgical intervention (if indicated)

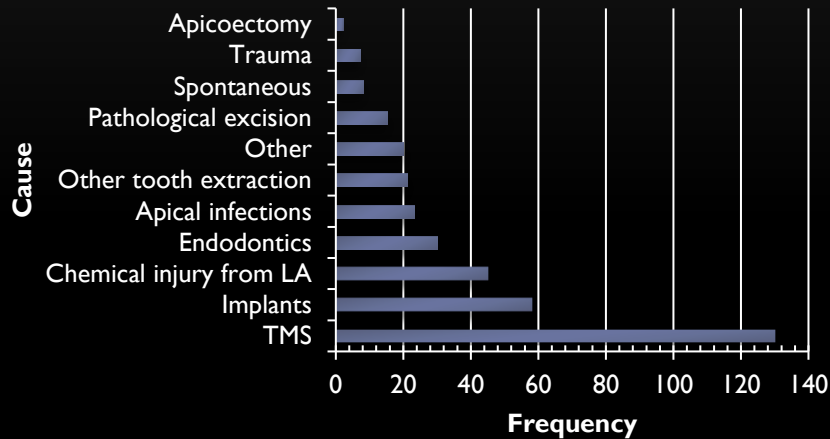


Nerve injuries related to dentistry

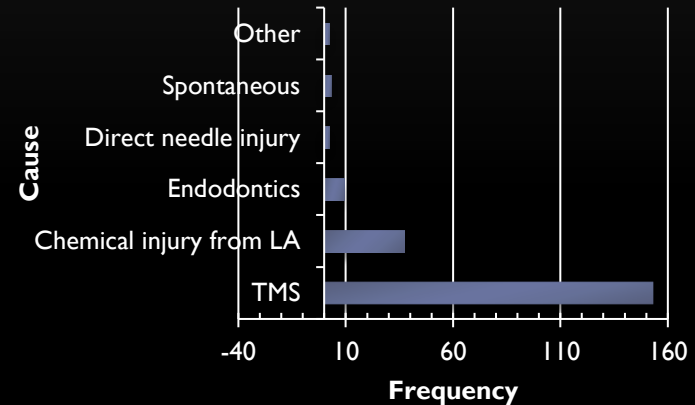
Causes

- ▶ Summary of nerve injury patients March 2008 –2016
- ▶ 400 IANI patients (73% F: 26.8% M; mean age = 46.5 years [range 18 – 85])
- ▶ 214 LNI patients (64.5% F: 34.6% M; mean age = 38.6 years [range 20 -73])

Causes of IANI's



Causes of LNI



Operative risk

Preventing Local anaesthetic nerve injuries (LANIs)

Block
injections
cause nerve
injuries



BDJ
BRITISH DENTAL JOURNAL

Access
To read this story in full you will need to login or make a payment (see right).

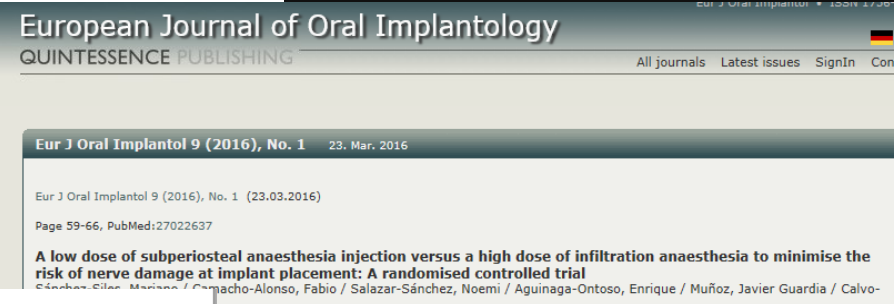
nature.com > Journal home > Table of Contents

Research

British Dental Journal **214**, 633 - 642 (2013)
Published online: 21 June 2013 | doi:10.1038/sj.bdj.2013.583
Subject terms: [Anaesthesia and sedation](#) | [Oral surgery](#) | [Medical m](#)

UK dentists' experience of iatrogenic trigeminal nerve injuries in relation to routine dental procedures: why, when and how often?

T. Renton¹, H. Janjua², J. E. Gallagher², M. Dalgleish⁴ & Z. Yilmaz²



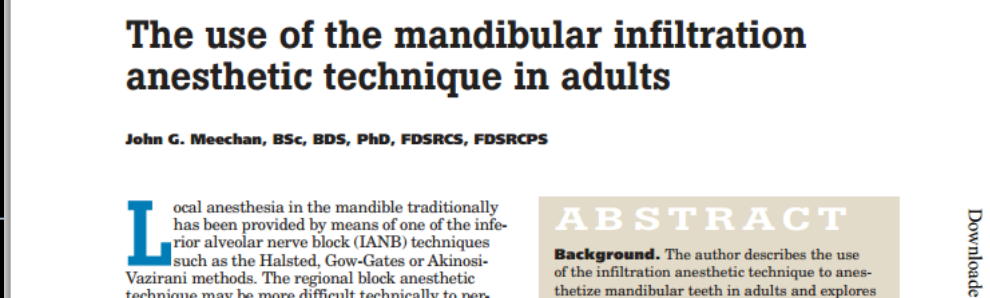
European Journal of Oral Implantology
QUINTESSENCE PUBLISHING

All journals Latest issues SignIn Con

Eur J Oral Implantol 9 (2016), No. 1 23. Mar. 2016

Eur J Oral Implantol 9 (2016), No. 1 (23.03.2016)
Page 59-66, PubMed:27022637

A low dose of subperiosteal anaesthesia injection versus a high dose of infiltration anaesthesia to minimise the risk of nerve damage at implant placement: A randomised controlled trial
Sánchez-Elices, Mercedes / Domacho-Alonso, Fabio / Salazar-Sánchez, Noemi / Aguinaga-Ontoso, Enrique / Muñoz, Javier Guardia / Calvo-



The use of the mandibular infiltration anaesthetic technique in adults

John G. Meechan, BSc, BDS, PhD, FDSRCS, FDSRCPs

ABSTRACT

Background. The author describes the use of the infiltration anaesthetic technique to anesthetize mandibular teeth in adults and explores

Local anesthesia in the mandible traditionally has been provided by means of one of the inferior alveolar nerve block (IANB) techniques such as the Halsted, Gow-Gates or Akinosi-Vazirani methods. The regional block anaesthetic technique may be more difficult technically to perform

Download

her a low-dose subperiosteal anaesthesia is effective in minimising risks of inferior alveolar nerve damage at compared to high-dose infiltration anaesthesia.

hundred and twenty patients requiring the placement of a single implant in order to replace a missing first allocated to two groups: group A (awake hemilip) subperiosteal crestal injection equal to 0.9 ml of articaine group B (numb hemilip) infiltration equal to 7.2 ml of articaine with 0.5% epinephrine in the vestibular sensory control using sensory tests was carried out in all patients. Outcome measures were neurological and postoperative visual analogue scale (VAS) scores for pain and swelling, and a questionnaire evaluating patients were followed for 1 week postoperatively.

ries of nerve injury. Seven days after surgery the postoperative VAS score for pain and swelling was lower in significant manner (difference = -3.41%; 95% CI: -5.57, -1.26; P = 0.002 and difference = -3.33%; 95% CI: respectively).

age occurred using either anaesthesia types, therefore the choice of type of anaesthesia is a subjective it may be preferable to use a low dose (0.9 ml) of subperiosteal anaesthesia, since it is unnecessary to deliver a single mandibular molar implant site.

inferior alveolar nerve, local anaesthesia

order article as PDF-file (20.00 €)

Possible mechanisms

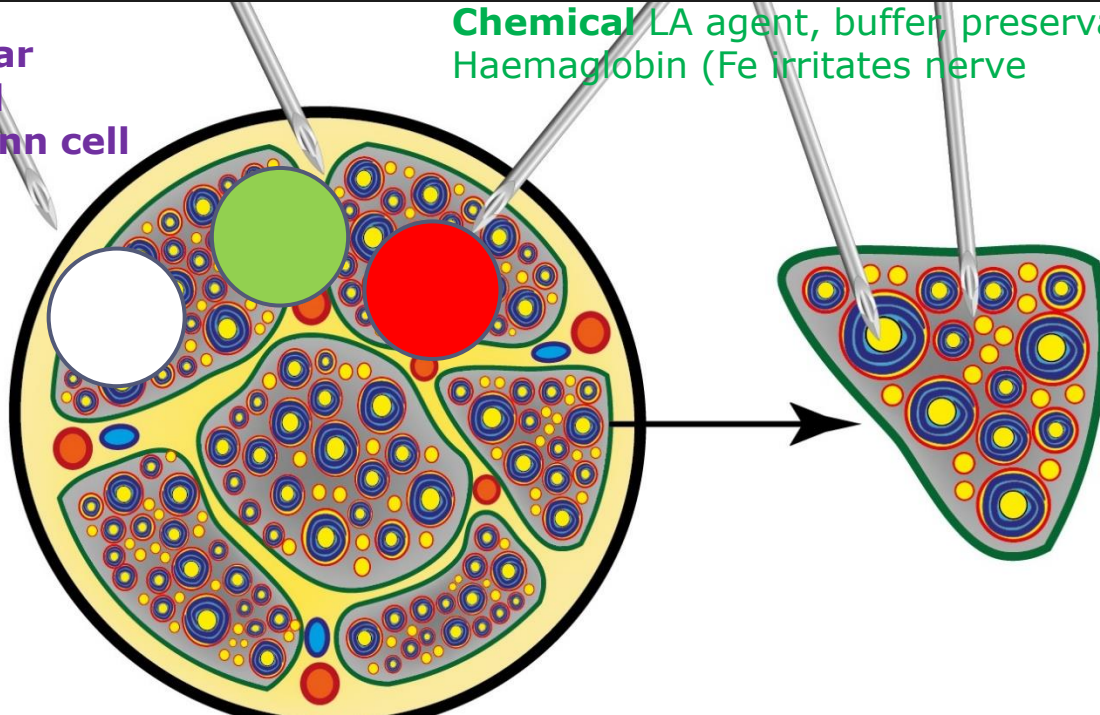
Extraneural
Intra neural
Intra fascicular
Neural axonal
Neural schwann cell
(myelin)
Blood vessels
Fat

Mechanism of trauma

Mechanical Direct needle/ indirect scarring

Pressure ischaemia from bleed or LA

Chemical LA agent, buffer, preservative, carrier
Haemoglobin (Fe irritates nerve)



Risk factors for persistent neuropathy related to IDBs

In order to minimise complications related to dental LA you need to consider modifying the following risks:

- **Block anaesthesia** Nerve block injections should be undertaken without intent on direct IDBs. Patients who experience the 'funny bone' neuralgia due to the IDB needle being placed too close to the inferior alveolar nerves experience persistent neuropathy (20)
- **Lingual nerve > IAN** Is this technique related or anatomically related (less fascicles, slower recovery). Perhaps the direct IDB approach may place the lingual nerve at increased risk of injury compared to indirect technique. (14)
- **Concentration of LA** Any increased concentration of any agent leads to increased risk of neurotoxicity (21)
- **Volume of LA** There is no evidence to support this suggestion. Volume is dependent upon the proximity, LA concentration, neural damage and patient factors. Some agents are neurotoxic, potentially at lower concentrations.
- **Multiple injections** Second or subsequent injections that impede directly or indirectly on the nerve are associated with the usual 'funny bone' neuralgic pain. Thus the patient does not self-protect, rendering the nerves more at risk of direct damage.
- **Severe pain on injection** 60% increased occurrence of persistent neuropathy after IDBs (21)
- **Type of LA Agent** Bupivacaine most neurotoxic of all LA agents
- **Type of vasoconstrictor?** The role of vasoconstrictor in nerve damage is unknown
- **Sedated or anaesthetized patients?** There is no evidence to support unresponsive patients not being able to protect themselves when neuralgia (funny bone reaction) occurs as the IDB needle encroaches on the nerve.
- **Lack of LA aspiration?** Again there is no evidence to support that aspiration of LA prevents persistent neuropathies but a pragmatic view may infer less chemical injected intra neurally reduces the risk of chemical nerve injury.

Block injections

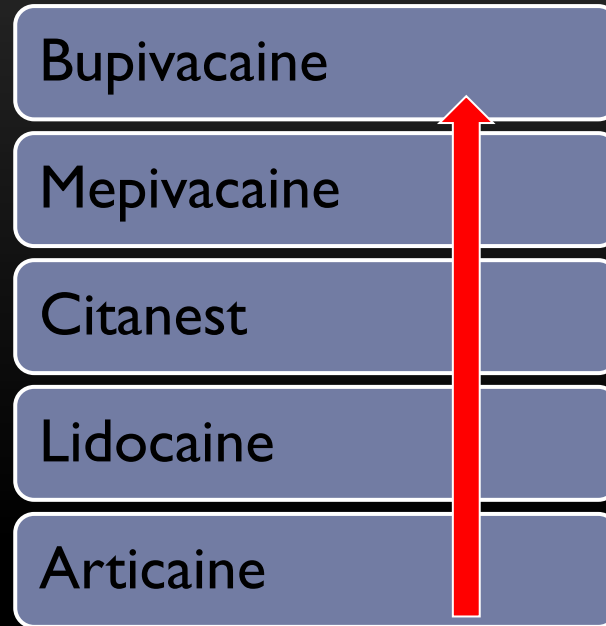
Multiple injections

Type and concentration of LA agents

Extreme pain during injections

Risks factors for Dental LA NIs

- **Block anaesthesia**
- **Lingual nerve > IAN**
 - Technique or Anatomy?
- **Concentration of LA agent**
- **Agent toxicity**
- **Multiple injections**
- **Severe pain on injection**
 - Smith and Lung 2006
- **Type of LA Agent**
 - Type of vasoconstrictor?
 - Sedated / anaesthetised patients?
 - Lack of LA aspiration?
- **Volume of LA?**
- **Speed of injection?**
- **Patient?**



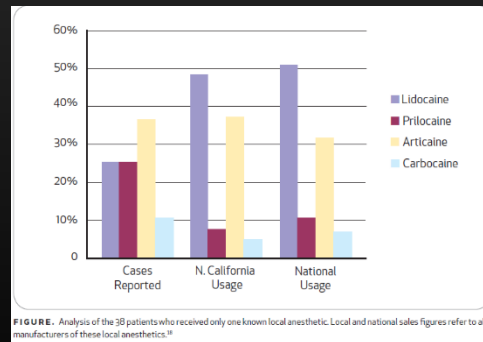
Increasing agent toxicity



Risk Factors LA concentration

Increased concentration of LA agent DOES increase risk of nerve injury!

- Hillerup & Jenson 2008
- Haas & Lennon 2009
- Garisto et al 2010
- Hillerup 2010
- Renton 2011
- Haas 2011
 - Articaine 21 times more likely to cause injury
- Hillerup et al 2011
- Hillerup et al 2011b
 - Rat nerve neurotoxicity 2vs 4% Articaine = concentration of Agent more likely neurotoxin than mechanical injury with saline
- Pogrel 2012
- Jacobs K report IFDAS 2015
- Piccini et al 2015
- Gaffen & Haas 2009



From Pogrel 2012

quently as the inferior alveolar nerve. During 2006–2008 alone, 64 cases of nonsurgical paresthesia were reported to PLP, a reported incidence of 1 in 609,000 injections. For the 2 local anesthetic drugs available in dental cartridges as 4% solutions, i.e., articaine and prilocaine, the frequencies of reporting of paresthesia were significantly greater than expected (χ^2 , exact binomial distribution; $p < 0.01$) based on their level of use by Ontario dentists. These data suggest that local anesthetic neurotoxicity may be at least partly involved in the development of postinjection paresthesia.



Dentistry is the **ONLY** healthcare profession taught to aim for nerves blindly during block injections!

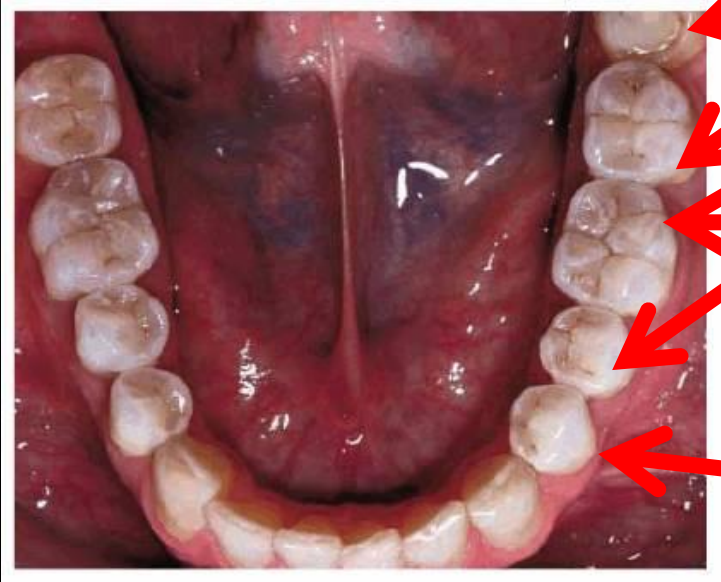

Infiltration techniques to avoid Nerve injury

Maxillary dentistry requires infiltration 2% lidocaine

Articaine 3.4x more effective in mandible infiltration

Smart LA' sub mucosal mandibular infiltration



▶ Intra ligamental lidocaine and buccal Articaine for M3M and M2Ms (rescue block when indicated)

▶ Articaine 4% Buccal Infiltration plus lingual Lidocaine 2% +/- IDB

▶ Articaine 4% Buccal Infiltration Post + anterior to the Mental foramen +/- Lingual Inf Lidocaine 2%

BI Articaine 4% > Lidocaine 2%. Can use Prilocaine 4% BUT only 55% success

▶ Buccal infiltration + Lingual both Lidocaine 2% Provides 90+% pulpal anaesthesia compared with 40-45% IDB

Prevention LA nerve injury – Use Infiltration dentistry is applicable to most dentistry

Evidence based for;

- ▶ **Pulpal anaesthesia in the anterior mandible compared with inferior dental block(IDBs)**

Meechan JG The use of the mandibular infiltration anesthetic technique in adults. J Am Dent Assoc. 2011 Sep;142 Suppl 3:19S-24S.

- ▶ **Restoration of pulpitic mandibular molars in adults**

Zain M, et al Comparison of Anaesthetic Efficacy of 4% Articaine Primary Buccal Infiltration Versus 2% Lidocaine Inferior Alveolar Nerve Block in Symptomatic Mandibular First Molar Teeth. J Coll Physicians Surg Pak. 2016 Jan;26(1):4-8.

Poorni S, et al Anesthetic efficacy of four percent articaine for pulpal anesthesia by using inferior alveolar nerve block and buccal infiltration techniques in patients with irreversible pulpitis: a prospective randomized double-blind clinical trial. J Endod. 2011 Dec;37(12):1603-7

- ▶ **Exodontia in adults and children**

Thakare A, Bhate K, Kathariya R Comparison of 4% articaine and 0.5% bupivacaine anesthetic efficacy in orthodontic extractions: prospective, randomized crossover study. Acta Anaesthesiol Taiwan. 2014 Jun;52(2):59-63.

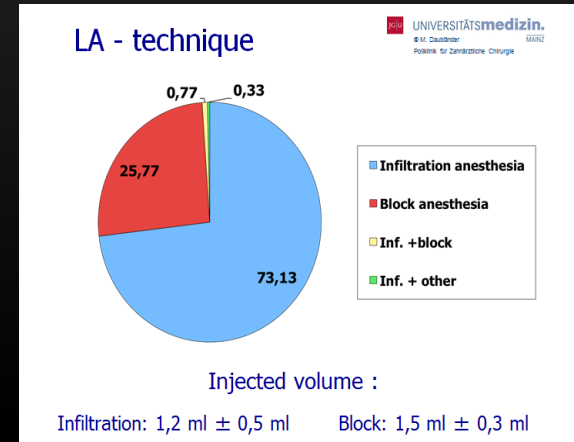
- ▶ **implant surgery**

Etöz OA, Er N, Demirbas AE. Supraperiosteal infiltration anesthesia safe enough to prevent inferior alveolar nerve during posterior mandibular **implant** surgery? Med Oral Patol Oral Cir Bucal. 2011 May 1;16(3):e386-9

- ▶ **periodontal surgery**

- ▶ -- **improved patient comfort Patients will undoubtedly prefer having full** -----
▶ **lingual sensation and shorter duration LA anaesthesia after dental treatment**

**2014 survey German dental LA practise
74% using infiltration dentistry!**



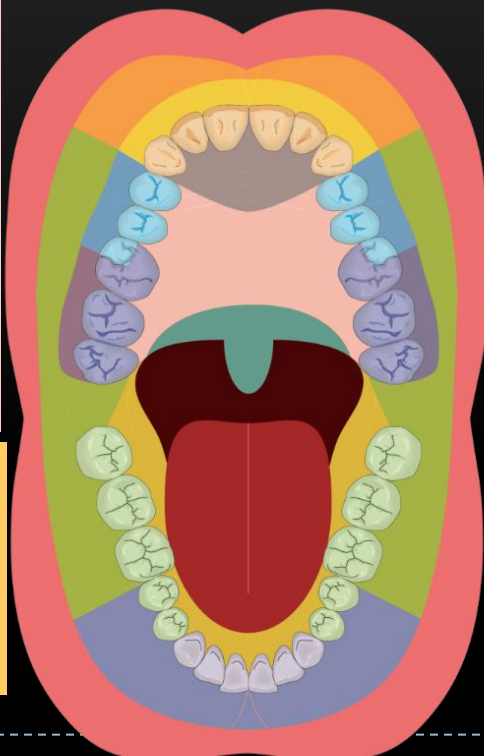
Courtesy Prof Monika Daublander

Infiltration dentistry is dependant upon the site and procedure

Maxillary dentistry can be performed entirely using Lidocaine 2% with adrenaline for all procedures
Buccal infiltration with intra-septal injections
No additional benefit using 4% Articaine
No palatal or incisal blocks are indicated

IDBS needed for

Posterior mandibular molar
Endodontic procedures may require IDBs or higher techniques (Gow Gates or Akinosi)



Mandibular 7s and 8s for perio, restorations or implants

Articaine 4% buccal infiltration and Lidocaine 2% lingual infiltrations OR for extractions intraligamental
If fails may need lidocaine IDB

Mandibular 1st molars for perio, restorations or implants

Articaine 4% buccal +/- Lidocaine 2% crestal or lingual infiltration s OR for extractions add lidocaine lingual of intra-ligamental

Mandibular premolars, canines incisors for perio, restorations or implants

Articaine buccal infiltration (incisal nerve block using 30% cartridge) adjacent not in the mental foramen and massage over region. If fails repeat or add crestal or lingual infiltration OR for extractions, intra-ligamental



Illustration modified from figure courtesy of Andrew Mason University Dundee

Prevention of LANI

Most importantly prevention of nerve injuries is possible? The long term significant problems seen in patients with these nerve injuries is exemplified in that the;

- ▶ **nerve injuries cannot be ‘fixed’.** We have to wait for resolution whilst managing the patient therapeutically using medical and psychological interventions. Thus there is no ‘fix’ for LA related nerve injuries only prevention.
- ▶ **25% of the nerve injuries are permanent**
- ▶ The injury is **related to high levels of dysthaesia** and pain mainly affecting the tongue with attendant social and psychological impact
- ▶ **No warning** and patient has ever heard of them and the **resultant isolation for the patient is severe.** At least with consent patients are aware of these rare but possible injuries.
 - ▶ 1 in 52K IDB NI permanent
- ▶ **There is significant stress to both dentist and patient.**



Should LA practice change?

▶ **Consent for LA**

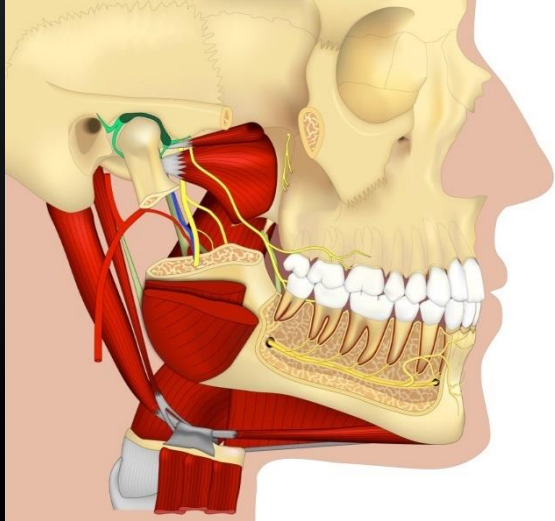
- ▶ Patients are routinely warned of a risk of nerve injury when routinely undergoing epidural or spinal injections
Reports the estimated that nerve injury resulting from neuroaxial blocks (epidurals, spinals and combined epidural with spinals) resulted in sensory or motor nerve injury in 1 in 24-54K patients (and paraplegia or death in 1 in 50-140K patients).
- ▶ Already in Germany most of Europe and US patients are routinely warned about risks associated with IDBs .

▶ **Tailored LA / Technique specific infiltration dentistry**

- ▶ Infiltration dentistry avoids the use of IDBs, thus preventing LA-related nerve injury, for which there is no cure and which is occurring more frequently than we were taught at dental school (1 in 14,000 blocks causes persistent neuropathy of which 25% are permanent).



Trigeminal Post Traumatic Neuropathy?

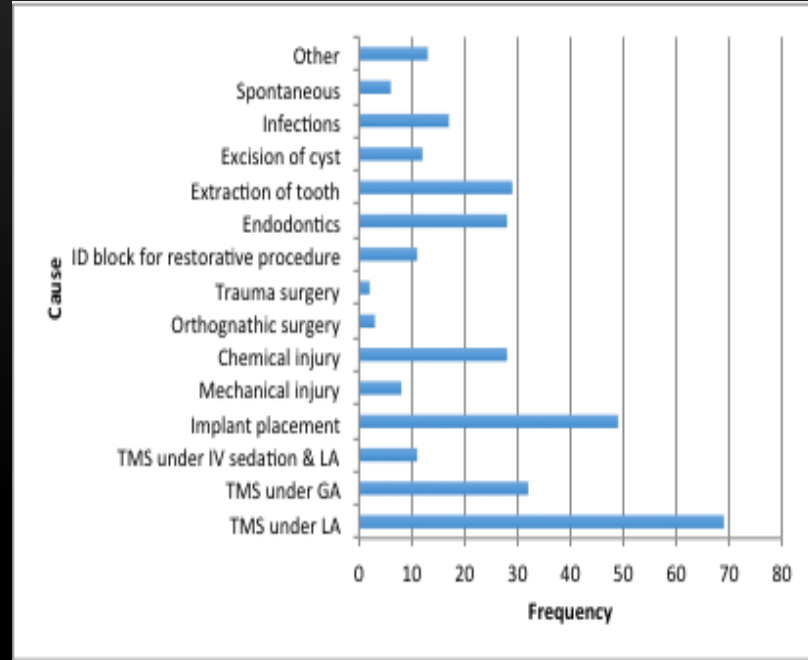


Local anaesthesia

Dental Implants

Endodontics

~~Third molar surgery~~



Complications related to dental implants

- ▶ Inferior alveolar nerve injuries are the most common nerve injuries related to implant surgery
- ▶ There are 3 cases of reported death after implant surgery due to lingual artery bleed out
 - ▶ Likely cause breach of the mylohyoid ridge by poor implant placement in 5-7 region
- ▶ 3 reported cases of lingual nerve injury
 - ▶ Likely due to lingual flap retraction

Review -17 different unusual complications were identified.

- ▶ damage to teeth adjacent to the implant,
- ▶ excessive bleeding resulting in hematoma of the floor of the mouth,
- ▶ mandibular fracture
- ▶ displacement of implants into the maxillary sinus.
- ▶ Benign paroxysmal positional vertigo
- ▶ plunging ranula were reported sporadically.

Quintessence International

QUINTESSENCE PUBLISHING

All journals Latest issues SignIn Contact

Quintessence Int 44 (2013), No. 10 30. Sep. 2013

Quintessence Int 44 (2013), No. 10 (30.09.2013)

Page 773-781, doi:10.3290/j.qi.a29936, PubMed:23772438

Review of unusual intraoperative and postoperative complications associated with endosseous implant placement

Wanner, Laura / Manegold-Brauer, Gwendolin / Brauer, Hans Ulrich

Objectives: Common complications associated with dental implant surgery are well recognized and are usually explained to patients during the process of informed consent. For the general dental practitioner, the periodontist, and the oral and maxillofacial surgeon, it is relevant to also be familiar with less frequent complications. This review gathers unusual complications of this surgical procedure and presents unique complications from single case reports.

Method and Materials: Studies were located using systematic searches in Medline and the Cochrane Library electronic databases. Key words included the terms "implant", "dental", "oral", "complication", "unusual", and "rare". References from the relevant articles were also double-checked. The review was limited to English and German language articles, published within the last 15 years.

Results: 17 different unusual complications were identified. The majority of studies report five different complications: permanent

Prevention of implant nerve injury


Incidence of nerve injury

What is the incidence of implant related nerve injuries?

We do not know!

? 0.01%- 3% - 40% ?

https://www.surveymonkey.com/s/IANI_SURVEY



What we do know

The incidence of implant related nerve injuries is rare but has a devastating impact on the patients involved

Prevention of Implant nerve injury

Risk factors

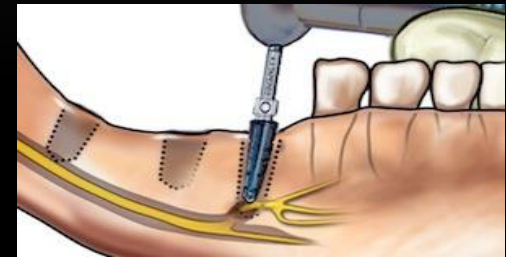
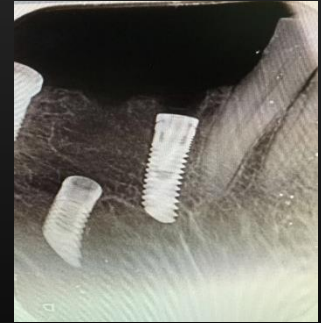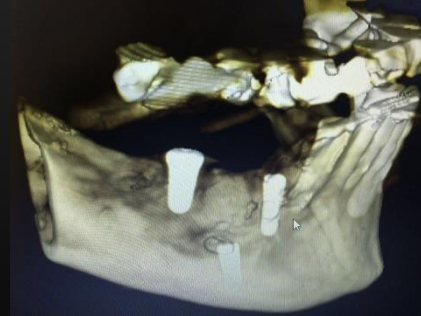Most nerve injuries occur:

- ▶ **In patients over 47 years**
- ▶ **In the parasymphyseal region**
- ▶ **During preparation of implant bed**
- ▶ **Using Implants > 10mm**
- ▶ **When the patient experiences severe pain**

during prep or implant placement

severe pain post surgery

Intraoperative bleed during prepping



Risk factors I

A. Poor risk assessment - Inadequate preoperative assessment and planning due to;

Lack of knowledge/inexperience

Inadequate informed consent and management of patient expectations

Lack of identification of existing pre-surgical neuropathy.

Additional risk assessment of mandibular premolars and molars

Poor planning

Know where the nerve is. Nerve localisation, risk factors when assessing (Mental loop, characteristics of IAN position in various sites of mandible)

Parasympyseal zone high risk.

The accuracy of estimating the position of the IDC based on clinical or CT scans is highlighted in the radiograph.

Insufficient Safety zone- Risk perpendicular to the nerve.

Poor surgical technique

Poor recognition of intraoperative problems

Poor implant placement

Selection of implants 10mm plus

(evidence supports shorter implants -short implant procedure and minimise morbidity)

Poor Planning

Insufficient Safety zone

Inappropriate radiographs

Inability to read CBCT

Using implants > 8mm

Operative

Poor technique reducing Safety zone/ lack use drill stops, guides/ intraoperative LCPAs
Lack of recognition risks bleeding/ drill sink

Post operative

Late recognition of nerve injury
Lack removal implant within 30 hours

Risk factors 2

B. Surgical procedure risk management;

Local Anaesthesia (infiltration anaesthesia)

Flap design

Use surgical guides (Chan, Chik, Pow, & Chow, 2013; Van Assche et al., 2007).

Using intraoperative radiographs (ITI)

Drill stops

C. Postoperative care should attend to:

Early post-operative recognition of neuropathy (HOMECHECK)

Prompt management of neuropathy (removal of implant if indicated)

Acute phase

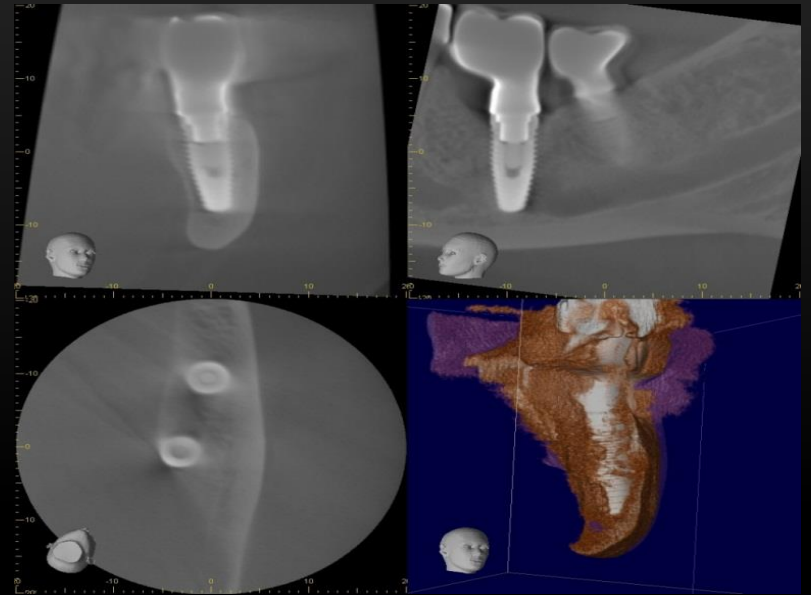
Late phase

Early or late post-operative infection

A Survey of the Opinion and Experience of UK Dentists: Part 2: Risk Assessment Strategies and the Management of Iatrogenic Trigeminal Nerve Injuries Related to Dental Implant Surgery. Yilmaz Z, Ucer C, Scher E, Suzuki J, **Renton T**. Implant Dent. 2017 Jan 25. doi: 10.1097/ID

Preventing implant related nerve injury

- Treatment need?
- Correct patient?
 - History clinical examination
- Consent
 - Indication for treatment
 - Guidelines
 - Risks
- **Planning Risk assessment**
 - **Clinical**
 - **Radiographic** When is CBCT recommended? Who reads CBCT?
 - **Safety zone**
- LA protocol
 - Articaine as infiltration only
Peterson 2004; Heller & Shankland 2001
- **Technique most drills longer than implants**
- **Post operative care**



Preventing implant related nerve injury

Are implants indicated?

▶ Explore patients expectations

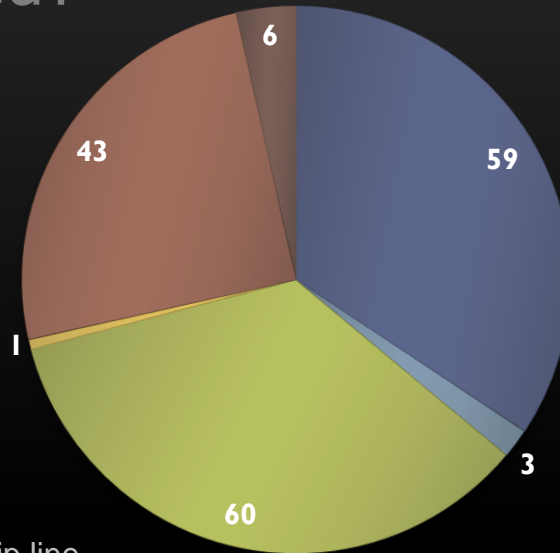
• Medical History

- Smoker
- Compromised immunity
- MRONJ risk

• Clinical

- Poor Oral hygiene
- Periodontal disease
- Bone mapping aesthetics, soft tissue, lip line

• Consent



■ Yes- SAC classification

■ Yes- Cologne ABC score

■ I follow the FGDP/GDC guidelines "Training Standards in Implant Dentistry"

**Contraindicated in patients with periodontal disease, smokers, bruxists, immunosuppressed.
The reality is only 57% of implants survive 10 years**

Assessment

Who actually assesses the risk?

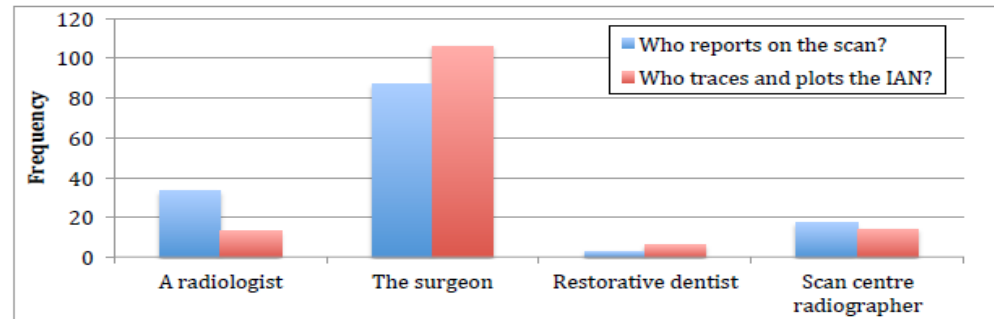
- Clinical
 - OH, Perio
 - Soft tissues and function
 - Hard tissue bone mapping, adjacent dentition
- Radiologic LCPA, DPT or CBCT?
 - Guidelines Faculty Dental Practitioners 9FGDP
 - SEDETEXTCT
- Informed consent
- Who assesses the risk?

Cone Beam Computed Tomography in Implant Dentistry: A Systematic Review Focusing on Guidelines, Indications, and Radiation Dose Risks

Michael M. Bornstein, PD Dr Med Dent¹/William C. Scarfe, BDS, FRACDS, MS²/
Vida M. Vaughn³/Reinhilde Jacobs, DDS, MSc, PhD, Dr hc⁴

Purpose: The aim of the paper is to identify, review, analyze, and summarize available evidence in three areas on the use of cross-sectional imaging, specifically maxillofacial cone beam computed tomography (CBCT) in pre- and postoperative dental implant therapy: (1) Available clinical use guidelines, (2) indications and contraindications for use, and (3) assessment of associated radiation dose risk. **Materials and Methods:** Three focused questions were developed to address the aims. A systematic literature review

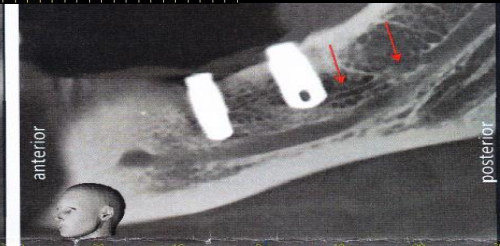
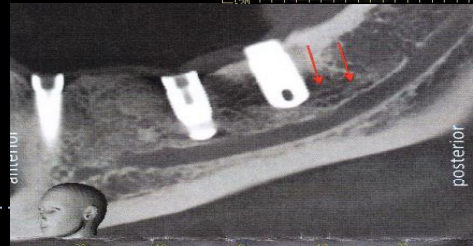
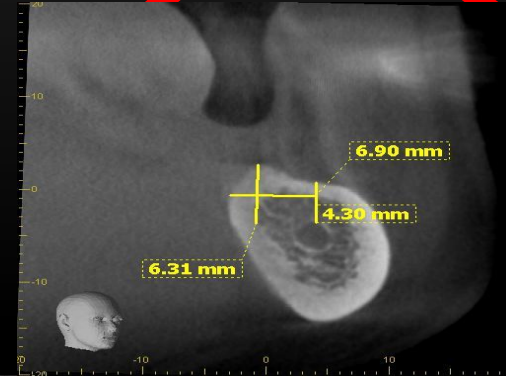
Figure 3: Indications of who reports on the scans (CBCT) and who traces and plots the IAN.



Managing preoperative risk

By good clinical and radiographic assessment

- ▶ LCPA inadequate for mandibular implants
- ▶ OPG/ DPT is standard
- ▶ Indications for CBCT
 - ▶ Mandibular implant surgery where depth and width of bone requires further assessment
 - ▶ Parasymphyseal region Premolar and first molar most problematic
 - ▶ **You MUST be able to read your own CBCTs**
 - ▶ Always get radiologist review to exclude pathology of all structures



Preoperative Risk assessment

Anterior extension of IAN

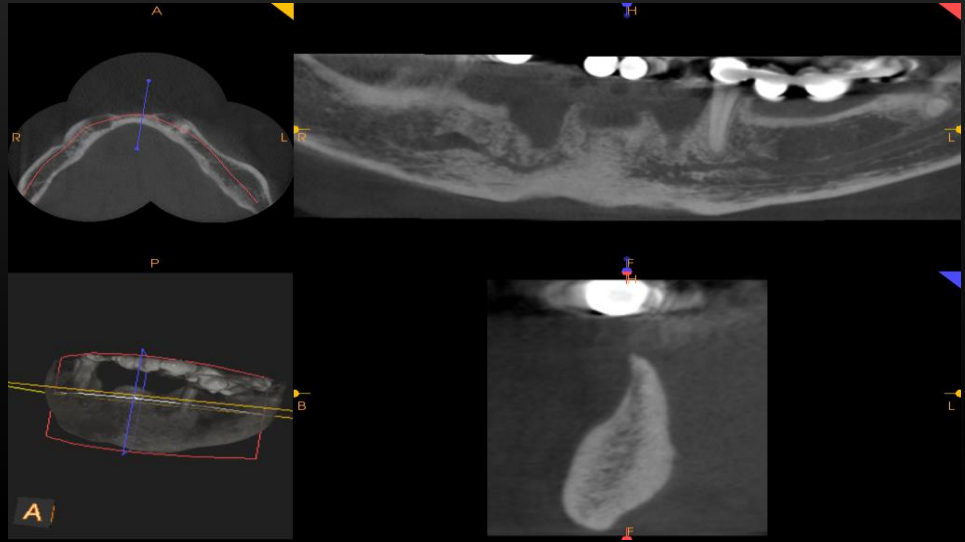
- ▶ OPG and DPT can over estimate the bone available for implants and CBCT can lead to over treatment

Both undesirable!!

▶ Assess IDC

- Position
- Bifid
- Cortication
- lateral branches
- Anterior extension

- ▶ **No evidence that CBCT reduces morbidity related to implant treatment**
-



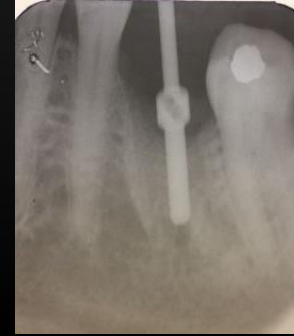Courtesy of Dr. David R. Nelson BDS, MSc.(Imp.Dent), Clinical Director, Cranmore Clinical Tutor, Institute of Postgraduate Dental Education, University of Central Lancashire Tutor, School of Dentistry, Queen's University Belfast. Fellow, International Team for Implantology



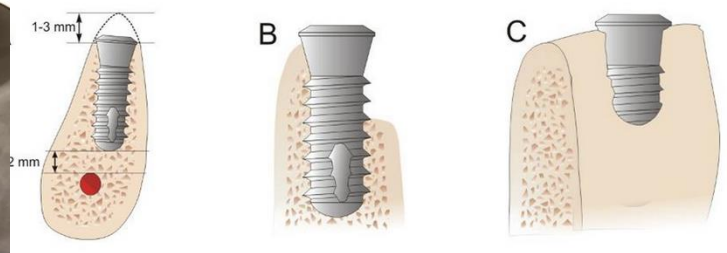
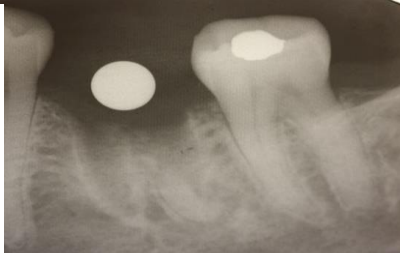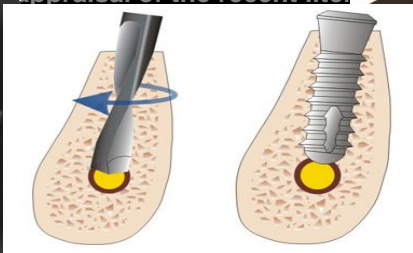
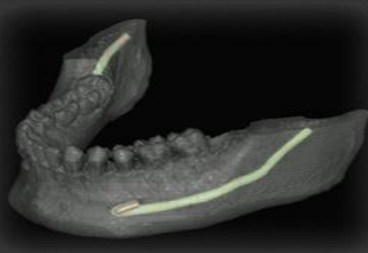
Managing Intraoperative risk

Implant prep and placement technique

- High risk mandibular premolars and molars
- Infiltration anaesthesia
- **Maximise safety zone**
 - More than 2 mm as in most implant systems drills are 1.5 mm longer than implants Short implants
 - Implants should not need to be longer than 8 mm
 - Use short implants
 - Use system where drill shorter than implant
- **Be aware of intraoperative risk factors**
 - Bleeding, sudden drop
 - Severe pain
- **Avoid complex treatment**
 - Bone grafting both mental and post mandibular have high morbidity
 - Lateralisation of IAN has high morbidity and poor evidence
 - Many nerve injuries are caused by over use of extensive soft tissue flaps

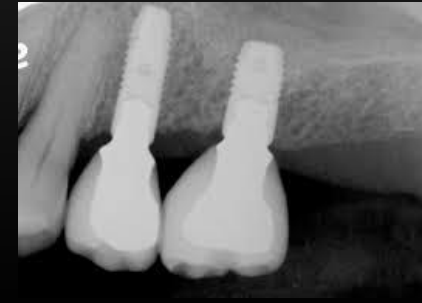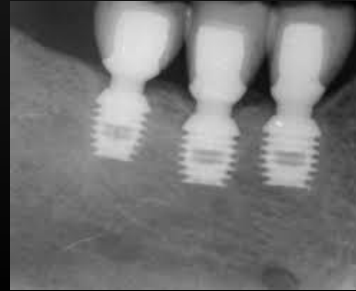

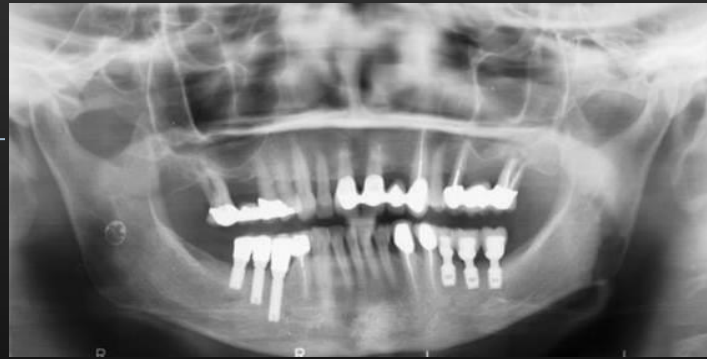
M Srinivasan, Lydia Vazquez Philippe Rieder, Osvaldo moraguez, Jean-Pierre Bernard Urs C. Belser **Efficacy and predictability of short dental implants (<8mm): a critical appraisal of the recent literature.** The International journal of oral & maxillofacial implants (Impact Factor: 1.91) 11/201



Short implants

- ▶ Strong evidence to support the use of short implants 5-8mm for mandibular cases
- ▶ Moderate evidence to support maxillary short implants (prevents the need for maxillary grafting)



Short Implants (5 to 8 mm) Versus Longer Implants (>8 mm) with Sinus Lifting in Atrophic Posterior Maxilla: A Meta-Analysis of RCTs

Tengfei Fan;* Yicun Li;* Wei-Wei Deng;* Tianfu Wu;* Wenfeng Zhang**†

ABSTRACT

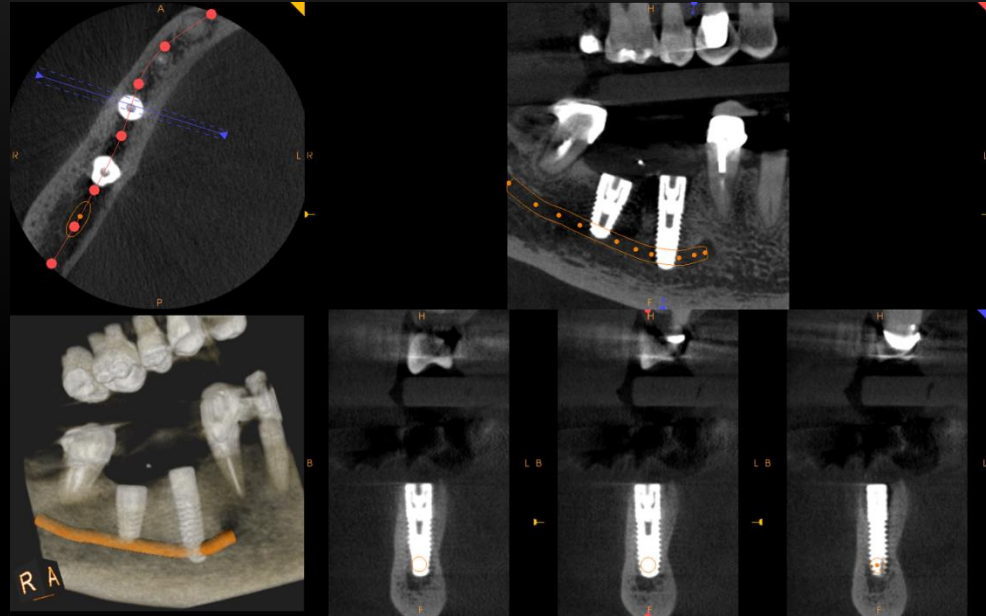
Objective: The specific purposes of this study were (1) to undertake a thorough systematic review and meta-analysis based only on randomized clinical trials (RCTs) to compare the rates of survival and complications of short implants to those of long implants; (2) to compare the surgical time and cost of short implants to those of long implants.

Methods: RCTs were identified from the major electronic databases (MEDLINE, Embase and Cochrane Library) using the keywords "dental implant," "short implant" and "atrophic maxilla," and a quantitative meta-analysis was conducted. The survival rate of implants and complications were the primary outcome measures, and other parameters assessed included costs and surgical time.

Chen MH, Shi JY **Clinical and Radiological Outcomes of Implants in Osteotome Sinus Floor Elevation with and without Grafting: A Systematic Review and a Meta-Analysis.** *J Prosthodont.* 2017 Jan 12. doi: 10.1111/jopr.12576. [Epub ahead of print] Fan T^{et al} **Short Implants (5 to 8 mm) Versus Longer Implants (>8 mm) with Sinus Lifting in Atrophic Posterior Maxilla: A Meta-Analysis of RCTs.** *Clin Implant Dent Relat Res.* 2017 Feb;19(1):207-215. doi: 10.1111/cid.12432. Epub 2016 Jun 13.

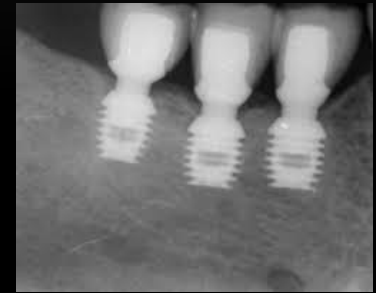
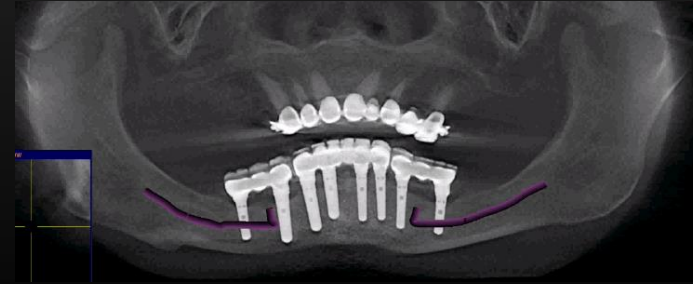
Computer guided surgery...

- ▶ Many types software
 - ▶ Helios
 - ▶ CDent
 - ▶ Simplant
- ▶ BUT still many injuries happen!

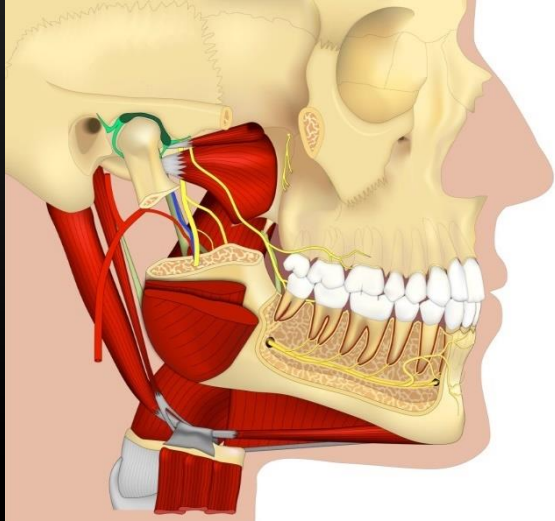


Surgical evidence for prevention of implant related nerve injuries

- ▶ Computer guided surgery (**none**)
- ▶ Use surgical guides (**moderate**)
 - ▶ (Chan, Chik, Pow, & Chow, 2013; Van Assche et al., 2007).
- ▶ Drill stops stock or tailored (**none**)
- ▶ ITI recommendation (**moderate**)
 - PAUSE after 60% planned depth OR 6mm
 - Take LCPA and check position
- ▶ **USE SHORT IMPLANTS** less than 10 mm for parasymphyseal region (**strong**) Implants should not need to be longer than 8 mm



Endodontic Post Traumatic Neuropathy?

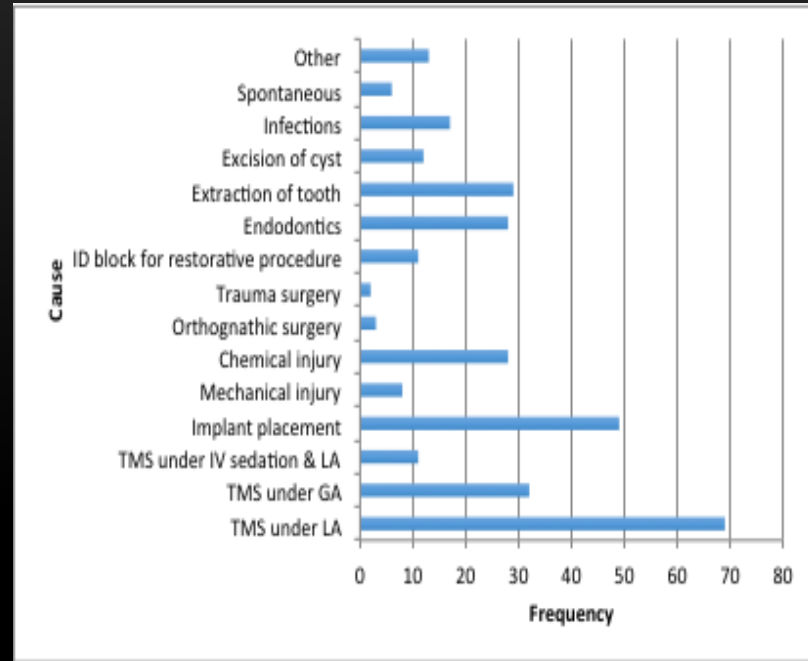


Local anaesthesia

Dental Implants

Endodontics

Third molar surgery



Endodontics-Related Paresthesia of the Mental and Inferior Alveolar Nerves: An Updated Review

Zahed Mohammadi, DMD, MSD

Contact Author

Dr. Mohammadi
Email: mohammadi_
zahed@yahoo.com



ABSTRACT

Paresthesia is a burning or prickling sensation or partial numbness resulting from neural injury. Paresthesia resulting from periapical pathosis or various stages of root canal treatment is of great importance in the field of endodontics. The purpose of this paper is to review paresthesia caused by periapical lesions, local anesthesia, cleaning, shaping and

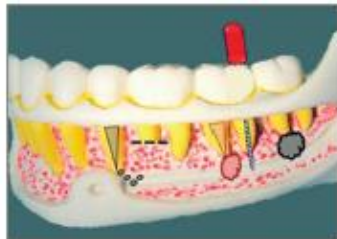

Figure 2: Schematic representation of the various causes of paresthesia due to endodontic problems. From the second premolar to the third molar, typical causes are extru-

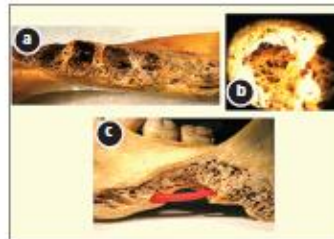


Figure 3: a) Jaw showing bone in the molar region. b) Higher magnification of the alveolar bone in the third molar region, notable for the presence of numerous vacu-

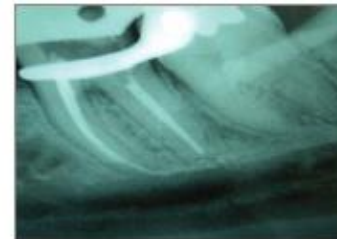
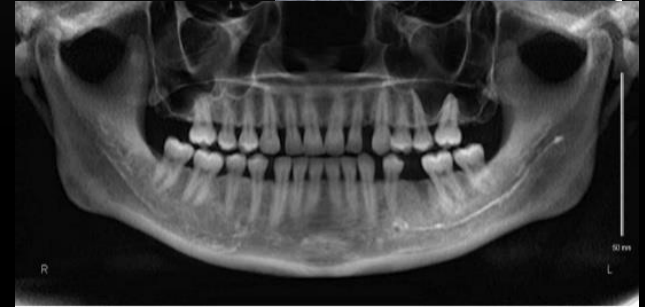
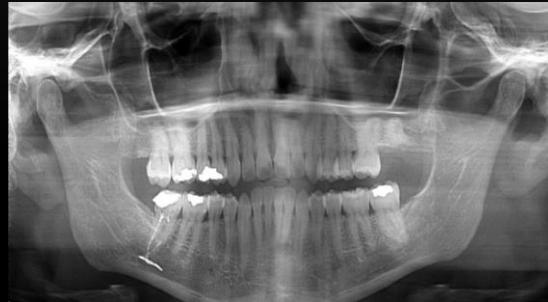
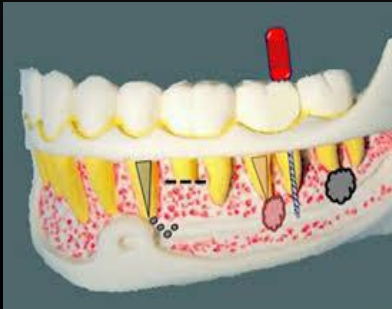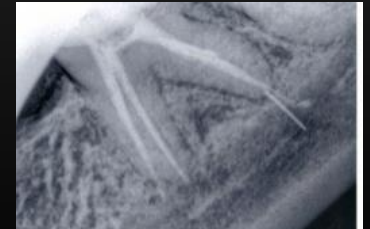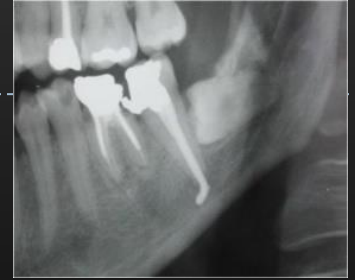Figure 4: Overfilling of sealer bordering the cortex of the mandibular canal.

Endodontic related nerve injuries

Mechanisms

- ▶ Mechanical compression canal due to overfill
- ▶ Direct mechanical damage due to over instrumentation
- ▶ Haemorrhage with direct and indirect neural ischaemia
- ▶ **Loss of apical seal and chemical leakage and damage**
- ▶ Inflammation / infection



-
- ▶ Fanibunda K, Whitworth J, Steele J (1998) The management of thermomechanically compacted gutta percha extrusion in the inferior dental canal. Br Dent J. 1998 Apr 11; 184(7):330-2

Prevention of Endodontic related neuropathy: Risk factors

A. Inadequate preoperative assessment and planning due to;

- Lack of knowledge
- GDP (80% of referrals) GDP endodontic success rates are significant
- The American Association of Endodontists have made several recommendations for patients
- Inability to read the radiographs or CBCT
- Inadequate informed consent-all options provided and related risk benefits
- Lack of identification of existing pre-surgical neuropathy (periapical lesions)

Tooth apex position

Proximity to IDC

Related root morphology

(vs 85%)
Proximal of these

B. Premolar teeth & Proximity of tooth apex to IDC – 90% of the mandibular teeth in this series, were close to the IAN canal or premolars adjacent to the mental foramen. Proximity to the apex to the IAN/ breach apical seal and over chemical or instrumentation

- Tantanapornkul et al (33) reported the specificity and sensitivity of IAN to the tooth roots in 161 mandibular third molars 161; for it was 70% and 63% which were not significantly different.
- Patel et al (34) have reported on the use of CBCT in managing cone periapicals.

Poor technique

Lack apical seal

Over instrumentation

Over filling

the
70%

C. Poor technique

- Breach of apex causing pain during surgery on irrigation or during instrumentation and damage to periapical tissues
- Over instrumentation
- Overfill Detectable overfill occurred in 60% of cases and over instrumentation during preparation

D. Early recognition and intervention for Endodontic related nerve injuries

- ALWAYS undertake HOMECHECK , review patient and confirm neuropathy
- Neuropathy related to endodontics can be delayed and the patient must be seen 3-4 days post treatment (Renton et al unpublished).
- If nerve injury is suspected, you will already be aware of the proximity of the likely breach of apex, over instrumentation or deposition of endodontic material in the canal
- If there is suspected the material, the apex and or tooth must be removed within 4 weeks of placement in order to maximise recovery from nerve injury (9). If the patient is insistent on keeping the tooth urgent referral of the patient may be indicated for

Postoperative

Late recognition and late
tooth or overfill removal

Risk assessment Radiographic Proximity to the Inferior dental canal (IDC)

Mandibular teeth proximal to the IAN canal

- ▶ Apex of the tooth may be adjacent or intruding into the IDC canal and any small degree of leakage or overfilling may compromise the IAN.
- ▶ Assessment of the proximity of the tooth apex to the IAN canal has become significantly improved with Cone Beam CT scanning (CBCT) with the attendant risk of additional radiation and may not provide significantly more information than a plane long cone radiograph.
- ▶ Most of CBCT assessment of tooth positioning relation to the IAN canal is based on M3M prior to extraction

Is there a “safety zone” in the mandibular premolar region where damage to the mental nerve can be avoided if periapical extrusion occurs?

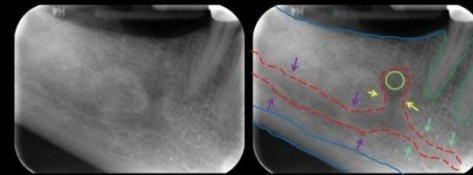
Wei Cheong Ngeow, BDS (Mal), FFDRCS (Ireland), FDSRCS (Eng), MDSc (Mal), AM (Mal)

Posted on June 16, 2010

Tags: [adverse reactions](#) [endodontics](#) [radiology](#)

Anatomic Relationship between the Inferior Alveolar Nerve and Dental Apex

Tilotta-Yasukawa and colleagues¹¹ determined the proximity of the apex of the premolars and molars in relation to the mandibular canal, as well



Tilotta-Yasukawa F, Millot S, El Haddioui A, Bravetti P, Gaudy JF. Labiomandibular paresthesia caused by endodontic treatment: an anatomic and clinical study. *Oral Surg Oral Med Oral Pathol Oral Radiol Endod.* 2006 Oct;102(4):e47-59.

Radiographic/ dental risk factors increasing for endo nerve injury

Predisposing tooth factor that may result in an adverse incident during root canal treatment	Potential adverse incident if tooth factor not recognised
Resorption defects where extent is not identified such as internal /external communicating with root canal and external surface of the root	Extrusion of endo filler /Hypochlorite accident
Suspicion of a perforation communicating with the external root surface	Extrusion of endo filler /Hypochlorite accident
Root fracture where there could be a potential communication of the root canal with external root surface	Extrusion of endo filler /Hypochlorite accident
Sclerosed root canal	Possible perforation with subsequent hypochlorite accident
Dens invaginatus	Possible perforation with Subsequent hypochlorite accident
Periapical lesions and other pathology (cysts)	Neurological injury (may occur if lesion close to IDC)
Lower molar teeth where root apices are is close proximity to the Inferior dental canal and or mental foramen	Neurological injury (over instrumentation, overfilling with obturation materials or sealer)

Recommendations to minimise Endo NI

Training Any tooth requiring endodontic therapy that is in close proximity to the IAN canal should require special attention. The practitioner should be trained in root length assessment and root canal preparation (European Endo Soc referral)

Radiographic **No specific radiological risk assessment yet**

CBCT should be considered an adjunct to two-dimensional imaging in dentistry.

Limited field of view CBCT systems can provide images of several teeth from approximately the same radiation dose as two periapical radiographs, and they may provide a dose savings over multiple traditional images in complex cases.

Post op radiograph before discharge to identify over fill

AAE and AAOMR joint position statement. Use of cone-beam-computed tomography in endodontics. American Association of Endodontists; American Academy of Oral and Maxillofacial Radiography. Pa Dent J (Harrisb). 2011 Jan-Feb;78(1):37-9.

Technical

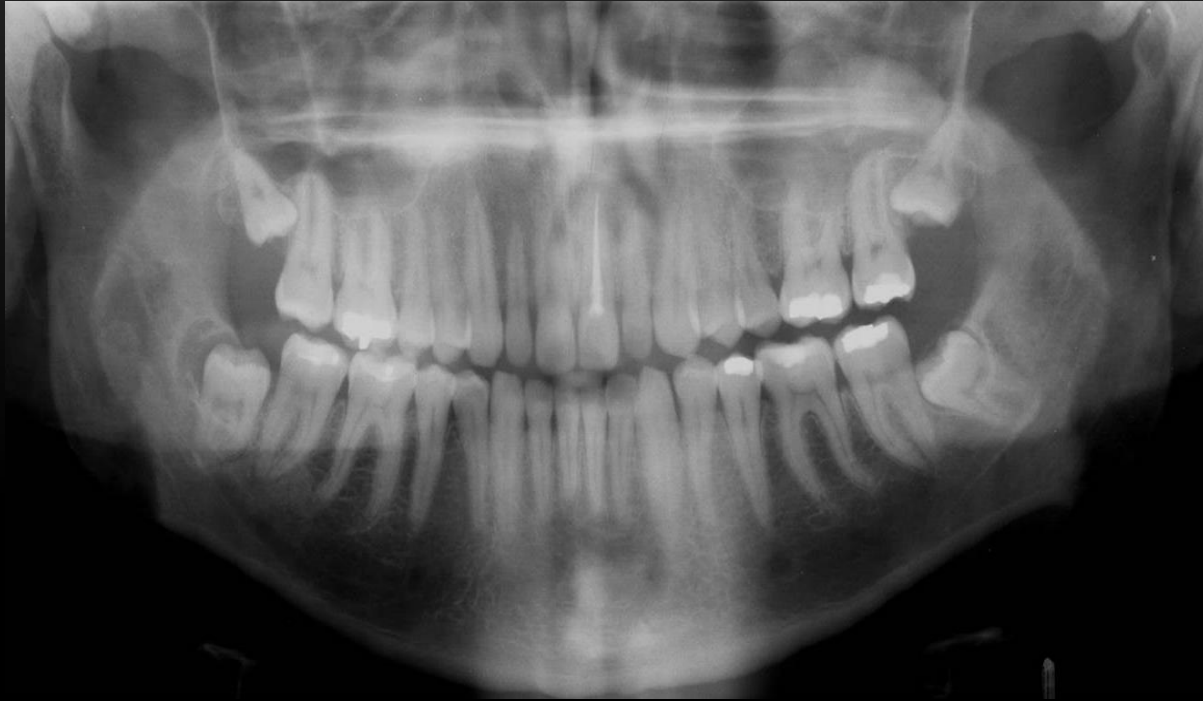- Working length
- Create apical plug
- Cold lateral condensation
- Apical extrusion of products may be increased by ultrasonics and minimised by using Endovac
- Always use a side venting needle with luer lock syringe
- Never bend the needle in the canal
- Never inject the hypochlorite into the canal it should be a very gentle passive movement of hypochlorite into the canal
- Never take the hypochlorite needle to the full working length
- Use of Rubber Dam
- Ensure that the needle is tightly bound to the luer lock syringe

Escoda-Francoli J, et al Inferior alveolar nerve damage because of overextended endodontic material: a problem of sealer cement biocompatibility? Endod. 2007 Dec;33(12):1484-9. Blanas N, Kienle F, Sándor GK. Inferior alveolar nerve injury caused by thermoplastic gutta-percha overextension. J Can Dent Assoc. 2004 Jun;70(6):384-7.

Apical extrusion of sodium hypochlorite activated with two laser systems and **ultrasonics**: a spectrophotometric analysis. Helvacioğlu Kivanç B, Deniz Arısu H, Yanar NÖ, Silah HM, İnam R, Görgül G. BMC Oral Health. 2015 Jun 26;15:71



Preventing M3M surgery related PTN



Mandibular third molar surgery

Lingual and Inferior alveolar nerves (IAN) injuries --- Risk factors

Lingual nerve

- ▶ Age of the patient
- ▶ Poor surgical technique
 - ▶ Junior surgeons
 - ▶ Duration of surgery
 - ▶ Lingual access surgery
 - ▶ Distal bone removal and lingual nerve injury
 - ▶ Use Buccal approach
 - ▶ Minimal access
 - ▶ 'aberrant' Lingual nerve anatomy
 - ▶ 11-18% of lingual nerve above alveolar crest distal to M3Ms

Inferior alveolar nerve

- ▶ Age of the patient
- Intra-operative exposure of the nerve
- Un-erupted tooth
- ▶ Poor Radiographic risk assessment
 - ▶ Perforation of tooth roots by IDC
 - ▶ Proximity of tooth roots to inferior dental canal (IDC)
 - ▶ Plain film
 - ▶ IDC loss LD
 - ▶ Darkening of roots
 - ▶ Deviation of IDC
 - ▶ CBCT lack cortication, distortion of canal. Lingual IDC

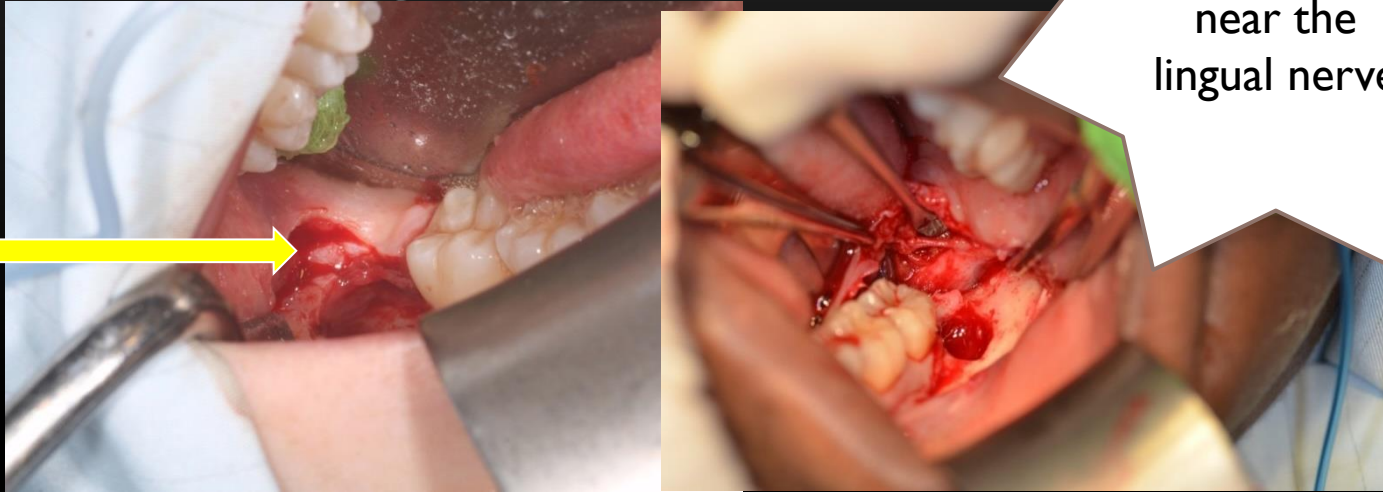
Acta Odontol Scand. 2013 Jul 4. The importance of a good evaluation in order to prevent oral nerve injuries: A review. Céspedes-Sánchez JM, Ayuso-Montero R, Mari-Roig A, Arranz-Obispo C, López-López J. 662 were obtained from the search, from which 25 were selected accomplishing the inclusion criteria. Moreover, seven important articles were selected from the references of the ones mentioned, obtaining a total of 32 articles for the review.

Renton T, McGurk M. Brit J Oral Maxillofac Surg 2001; 39: 423-428 Acta Odontol Scand. 2013 Jul 4. [Epub ahead of print]

The importance of a good evaluation in order to prevent oral nerve injuries: A review. Céspedes-Sánchez JM, Ayuso-Montero R, Mari-Roig A, Arranz-Obispo C, López-López J. -----
662 were obtained from the search, from which 25 were selected accomplishing the inclusion criteria. Moreover, seven important articles were selected from the references of the ones mentioned, obtaining a total of 32 articles for the review.

Prevention LNI related to M3M surgery

Spot the lingual nerve!



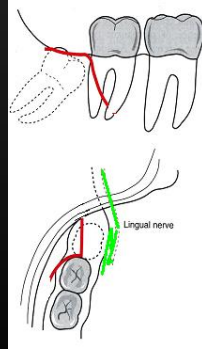
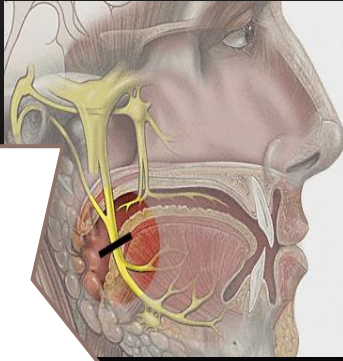
Avoid going
anywhere
near the
lingual nerve

Findings @ Lingual nerve exploration

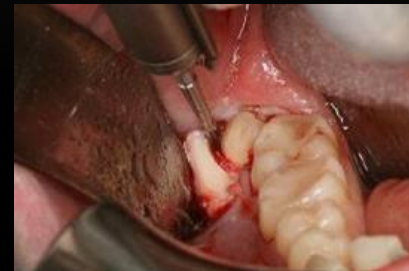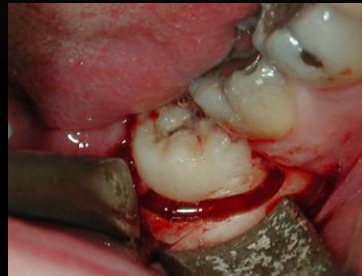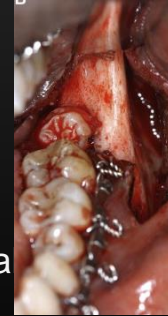


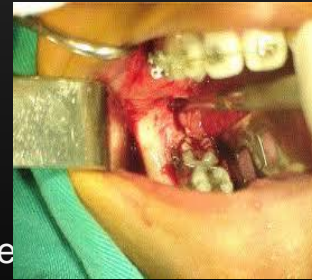Prevention– lingual nerve Minimal access prevents LNI

NEVER
Remove
distal bone
OR section
through the
tooth



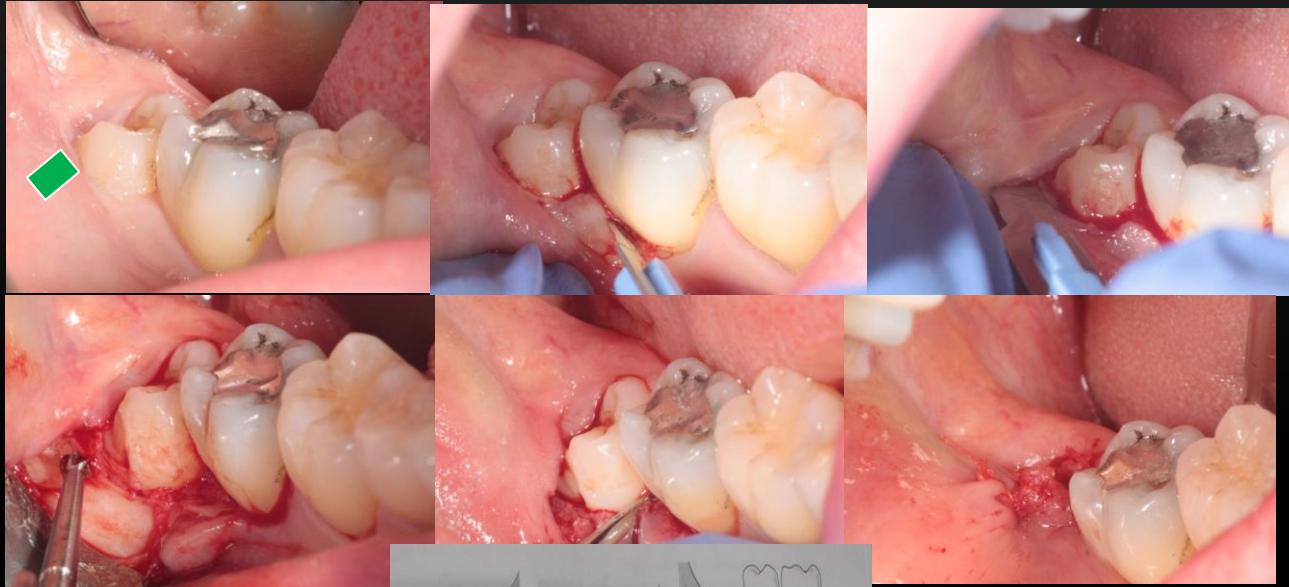
Old Technique 'Explode the patient'



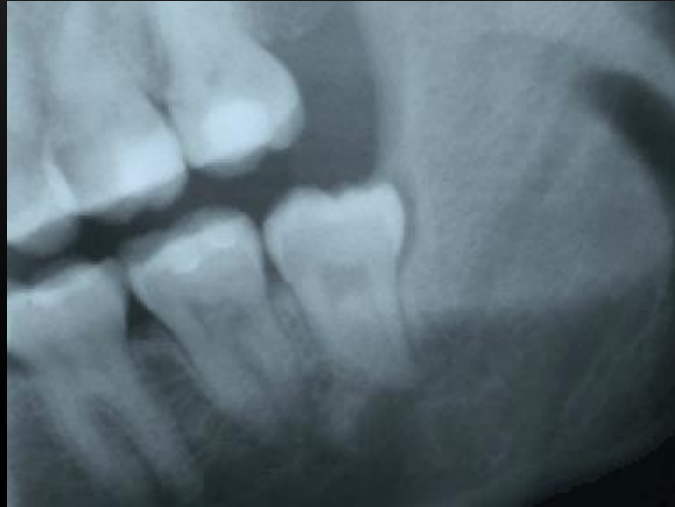Prevention

LNI related to M3M surgery

Buccal minimal access surgery



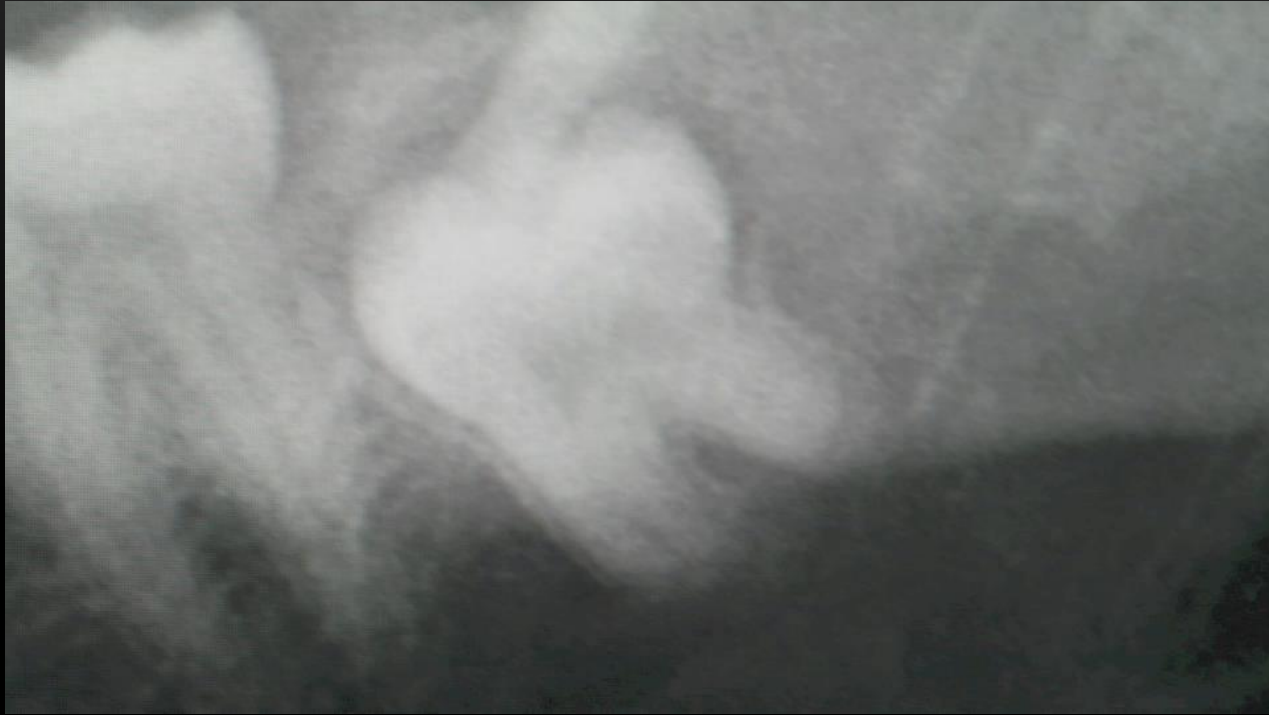Prevention of lingual nerve injury



Use the buccal approach with No distal bone removal

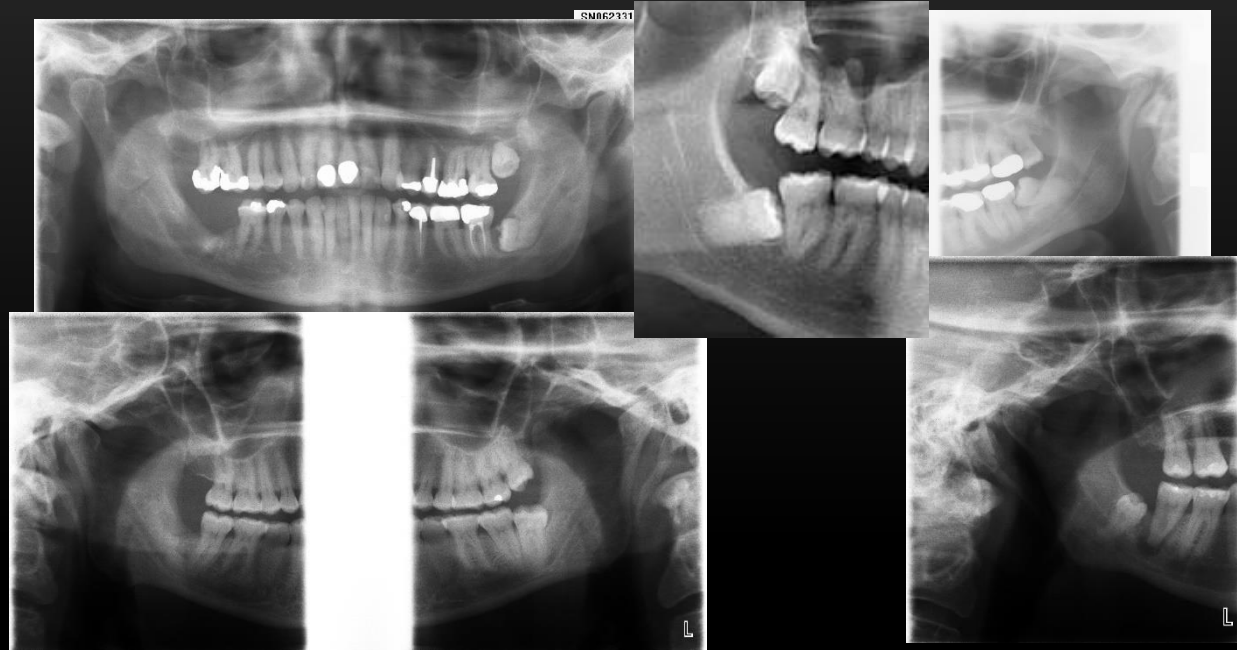

The buccal approach



Preventing inferior alveolar nerve injury

Risk assessment



Céspedes-Sánchez JM, Ayuso-Montero R, Marí-Roig A, Arranz-Obispo C, López-López J The importance of a good evaluation in order to prevent oral nerve injuries: A review. *Acta Odontol Scand.*2013 Jul 4.

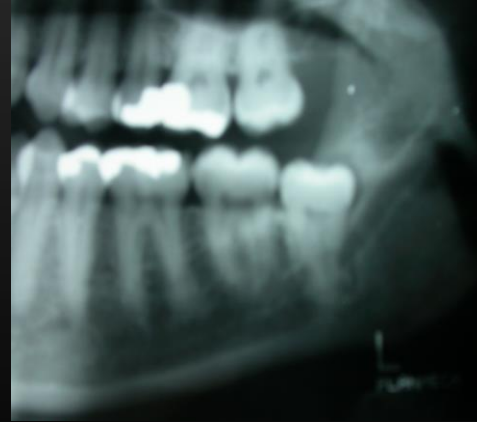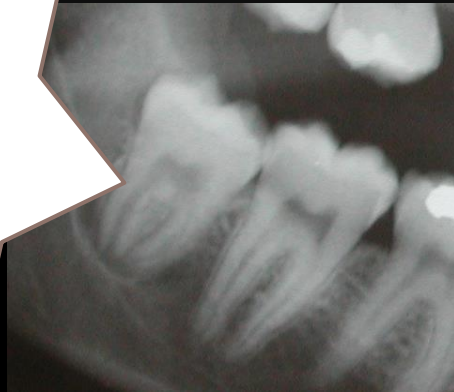Factors that are associated with injury to the IAN in high-risk patients after removal of third Molars. Selvi, Dodson, Nattestad, Robertson, Tolstunov. *BJOMS* 51 (2013) 868–873. with permission.

Risk assessment using plain films

Radiographic factors

- Diversion of the canal
- Darkening of the root
- Interruption of the canal LD

Recognise
plain film risk
factors
If high risk -
CBCT



NEW

- Juxta-apical area
- Deviation of canal
- Narrowing / darkening of roots

Renton T, Hankins M, Sproate C, McGurk M. A randomised controlled clinical trial to compare the incidence of injury to the inferior alveolar nerve as a result of coronectomy and removal of mandibular third molars. *Br J Oral Maxillofac Surg.* 2005 Feb;43(1):7-12 Rood JP, Shehab BA. The radiological prediction of inferior alveolar nerve injury during third molar surgery. *Br J Oral Maxillofac Surg.* 1990 Feb;28(1):20-5 Rud J. Third molar surgery: perforation of the inferior dental nerve through the root. *Tandlaegebladet.* 1983 Oct;87(19):659-67. No abstract available.

Risk assessment using plain films

Risk

- 0.5% of cases permanently
- 2% of cases temporarily

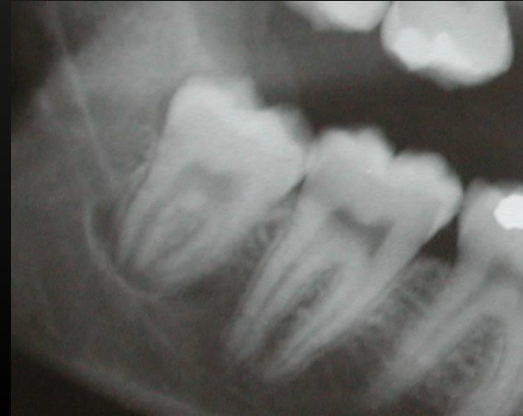BUT if the teeth are superimposed on the IAN canal

- 20% temporary
- 2% permanent

Risk factors

- increased age
- difficulty of surgery
- proximity to the IAN canal

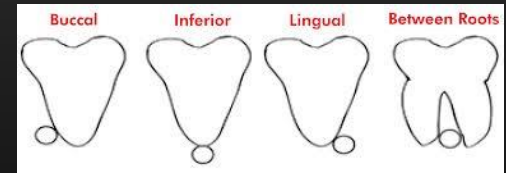
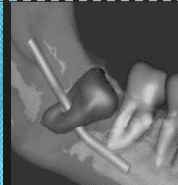
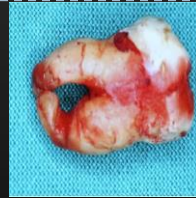↑ 10 x



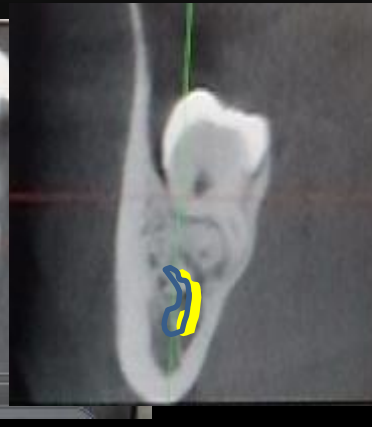
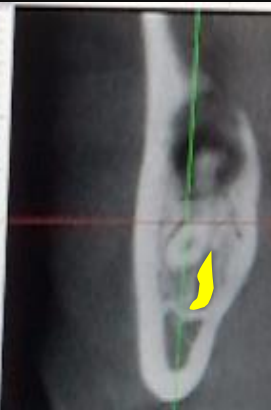
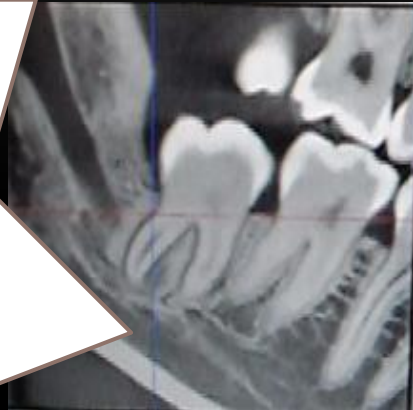
- Renton T, Hankins M, Sproate C, McGurk M. A randomised controlled clinical trial to compare the incidence of injury to the inferior alveolar nerve as a result of coronectomy and removal of mandibular third molars. *Br J Oral Maxillofac Surg.* 2005 Feb;43(1):7-12
- Wood JP, Shehab BA. The radiological prediction of inferior alveolar nerve injury during third molar surgery. *Br J Oral Maxillofac Surg.* 1990 Feb;28(1):20-5
- Rud J. Third molar surgery: perforation of the inferior dental nerve through the root. *Tandlaegebladet.* 1983 Oct;87(19):659-67. No abstract available.

CBCT Risk assessment M3M IANI Proximity to IDC and perforation

Perforation is very rare
How close does the nerve have to be?
The nerve doesn't have to 'perforate' tooth...



IAN at risk CBCT
Distortion of IDC
Lingual position
Loss of cortication
bifid
inter proximal



Comparison between cone beam computed tomography and panoramic radiography in the assessment of the position and proximity of the inferior alveolar nerve to impacted class C mandibular third molars. Dent Res J. 2011;8:203
J Oral Maxillofac Surg 68:1173-1178, 2010

DO not rely on radiologists report

Read the CBCT your self!

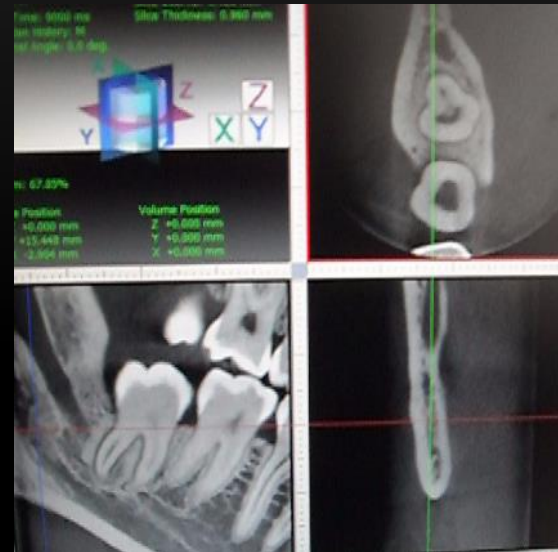
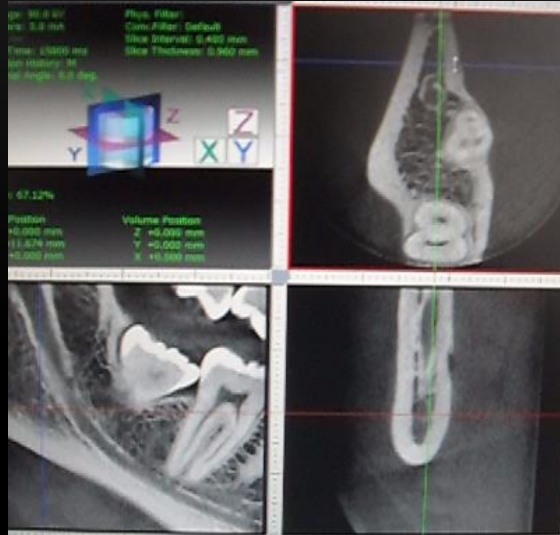
Prevention of IAN injury

Risk assessment Low or High?

Remove the tooth or coronectomy?

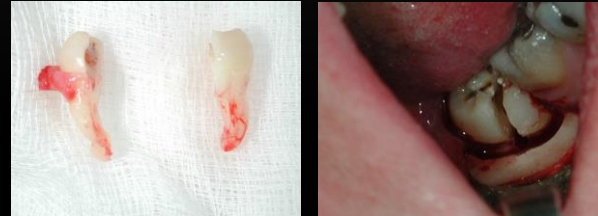Distant- remove 'Snake like' or Perf-Coronectomy



M3M Removal or Coronectomy?

- ▶ Patient healthy?
 - ▶ Patient reliable?
 - ▶ Tooth vital?
 - ▶ Tooth high risk-confirmed on CBCT inter radicular IAN?
- ▶ Yes to all
▶ No to any?
- ▶ Yes to all → Coronectomy
- ▶ No to any? → Removal

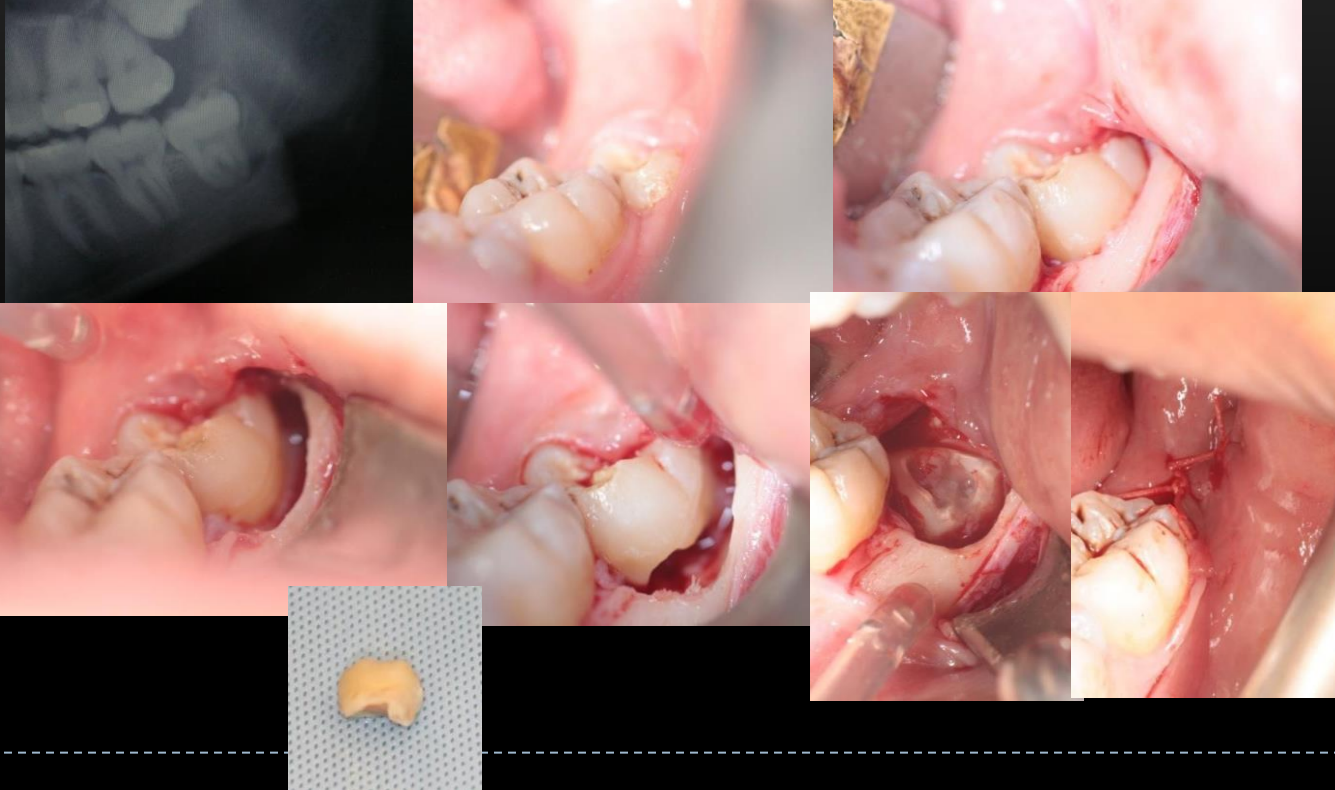
If tooth is non vital remove but section roots



Prevention of M3M IANI

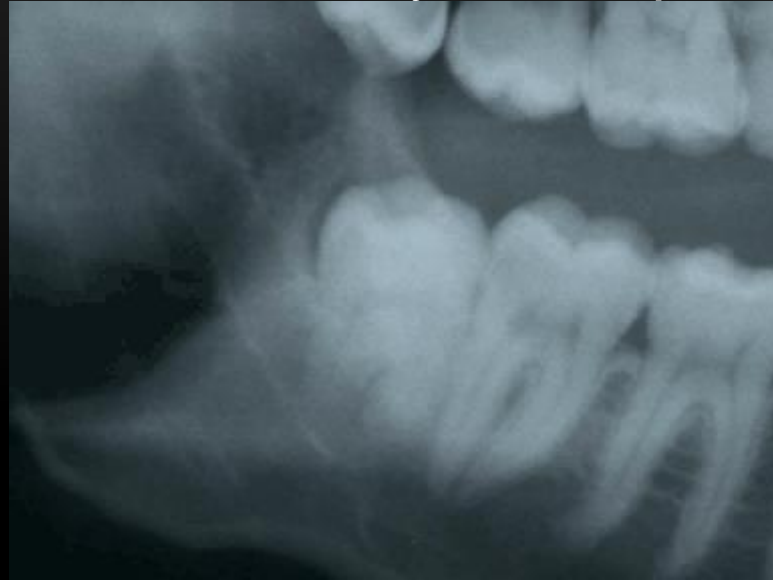Technique decision Coronectomy

Less than 4% of high risk M3Ms need a coronectomy (slides courtesy Gexala Umar)



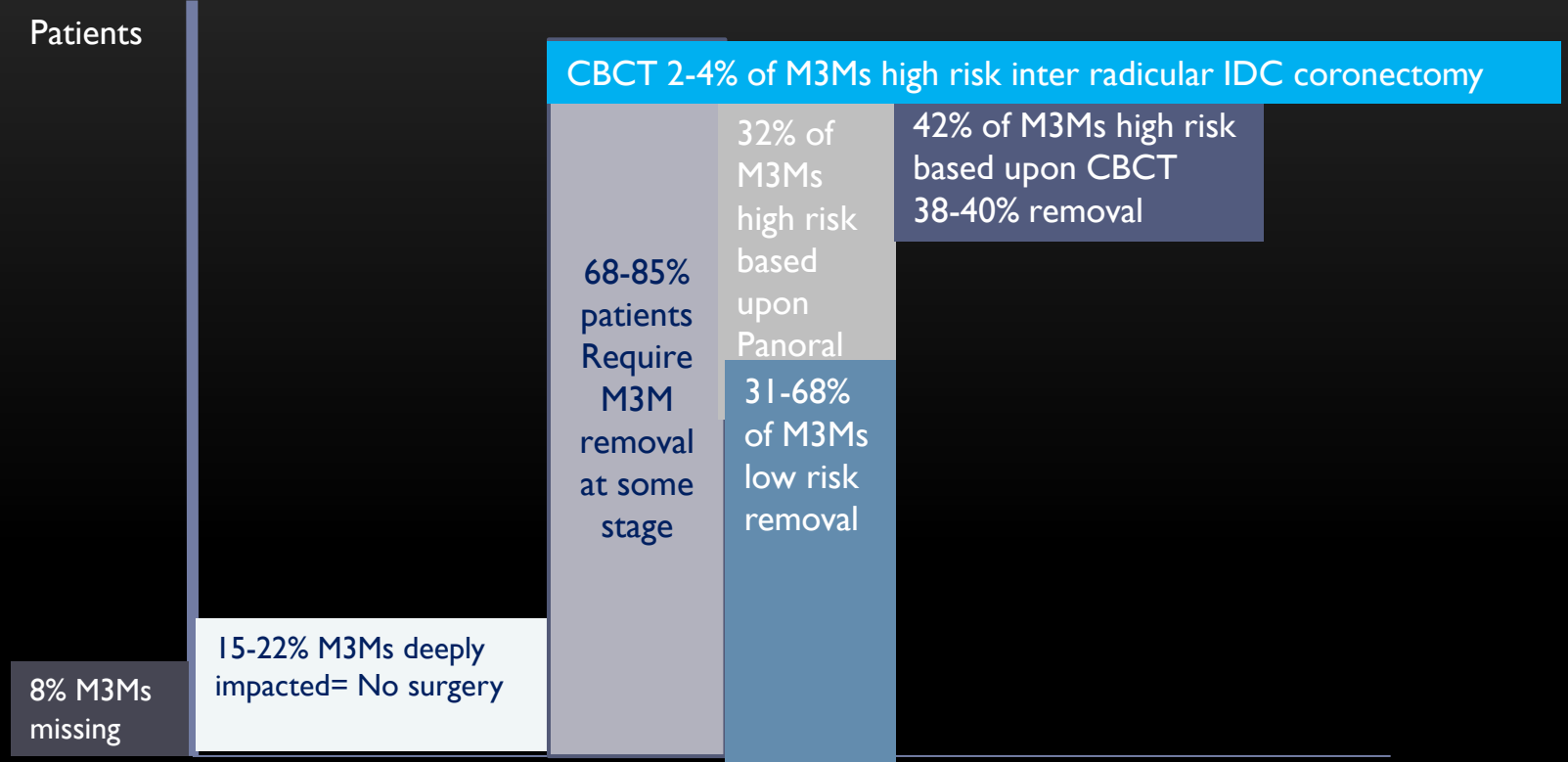
Prevention of IAN injury

Coronectomy technique




The Fate of M3Ms?


Only very few patients should undergo coronectomy




Overview



Why prevent these injuries?



How to prevent these injuries?



How to manage these injuries?



Management of Trigeminal Post traumatic neuropathy

Currently, there is **no consensus** on the optimal management of neuropathic pain exists and practices vary greatly worldwide.

Possible explanations for this include **difficulties in developing agreed diagnostic protocols and the coexistence of neuropathic, nociceptive and, occasionally, idiopathic pain in the same patient.**

Int. J. Oral Maxillofac. Surg. 2012; 41: 629-637
doi:10.1016/j.ijom.2011.11.002, available online at <http://www.sciencedirect.com>

International Journal of
**Oral &
Maxillofacial
Surgery**

Review Paper
Oral Surgery

Managing iatrogenic trigeminal nerve injury: a case series and review of the literature

T. Renton, Z. Yilmaz
King's College London Dental Institute,
Denmark Hill Campus, London, UK

T. Renton, Z. Yilmaz: Managing iatrogenic trigeminal nerve injury: a case series and review of the literature. Int. J. Oral Maxillofac. Surg. 2012; 41: 629-637. © 2011 International Association of Oral and Maxillofacial Surgeons. Published by Elsevier Ltd. All rights reserved.

Abstract. This study describes the management of 216 patients with post-traumatic iatrogenic lingual nerve injuries (LNIs; $n = 93$) and inferior alveolar nerve injuries (IANI; $n = 123$). At initial consultation, 6% IANI and 2% LNI patients had undergone significant resolution requiring no further reviews. Reassurance and counselling was adequate management for 51% IANI and 55% LNI patients. Systemic or topical medication was offered as pain relief to 5% of patients. Additional cognitive behaviour therapy (CBT) was offered to 8% of patients. Topical 5% lidocaine patches reduced pain and allodynia in 7% of IANI patients, most often used without any other form of management. A small percentage of IANI patients (4%) received a combination of therapies involving CBT, surgery, medication and 5% lidocaine patches. Exploratory surgery improved symptoms and reduced neuropathic area in 18 LNI and 15 IANI patients resulting in improved quality of life. In conclusion, the authors suggest a more diverse and perhaps holistic strategy for management of patients with iatrogenic trigeminal nerve injuries and recommend pragmatic assessment criteria for measurement of treatment success in these patients.

Accepted for publication 8 November 2011
Available online 10 February 2012





Treatments for accidental damage during surgery to the nerves supplying sensation to the tongue, lower lip and chin

Published:
16 April 2014

Authors:
Coulthard P, Kushnerev E, Yates JM, Walsh T, Patel N, Bailey E, Renton TF

Primary Review Group:
Oral Health Group

Review question

The main question addressed by this [review](#) is how effective are different treatments and what are the best timings for these treatments following accidental damage during surgery to the nerves that supply sensation to the tongue, lower lip and chin.

Background

The nerves (alveolar and lingual) supplying sensation to the tongue, lower lip and chin, may be injured as a result of surgical treatments to the mouth and face, including surgery to remove lower wisdom teeth. The vast majority (90%) of these

Authors' conclusions:

There is clearly a need for randomised controlled clinical trials to investigate the [effectiveness](#) of surgical, medical and psychological interventions for iatrogenic inferior alveolar and lingual nerve injuries. Primary outcomes of this [research](#) should include: patient-focused [morbidity](#) measures including altered sensation and pain, pain, quantitative sensory testing and the effects of delayed treatment.

Who is talking about this article?




Become a
citizen scientist

Management of Implant nerve injury

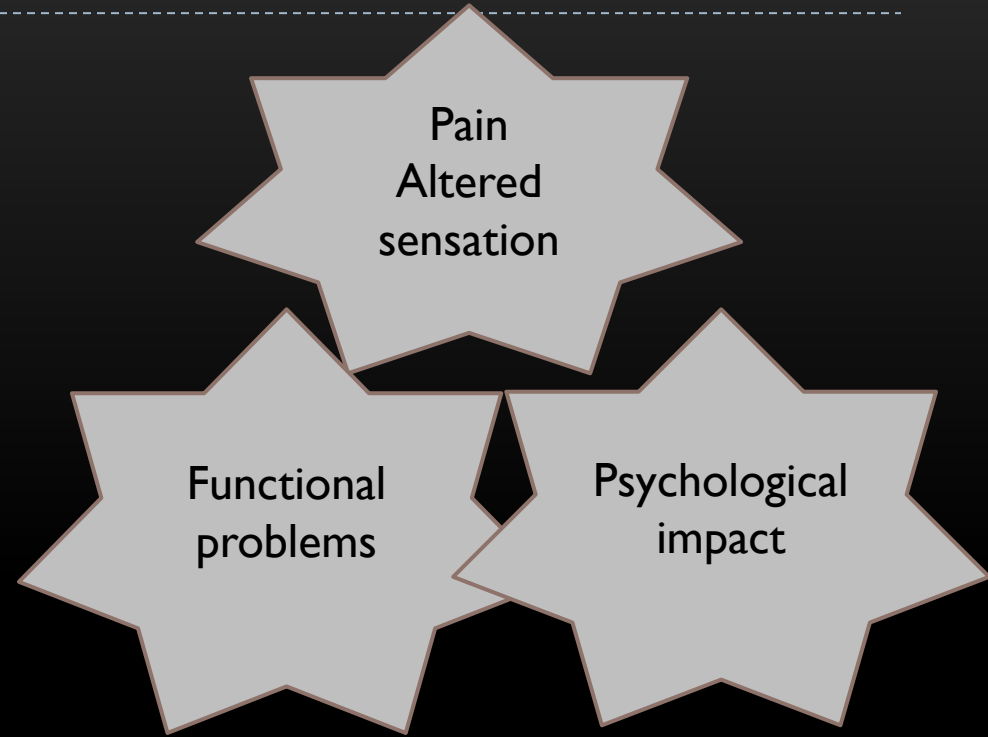Don't panic.....Say sorry!

- ▶ Sorry is NOT an admission of guilt it just shows you care!
- ▶ Disclose
- ▶ Apologise
- ▶ Remediate



Key patient assessment drives management

- ▶ Initial questions
 - ▶ Altered sensation / Numbness / Pain
 - ▶ Functional impact
 - ▶ Psychological impact
- ▶ Mechanism / cause
- ▶ Duration
- ▶ Site +/- Neuropathic area
- ▶ Onset

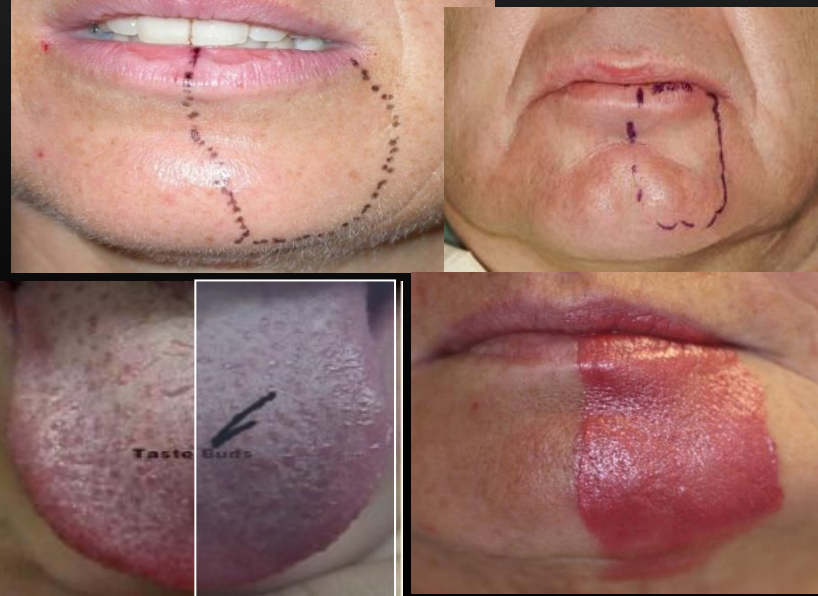

Management of Implant nerve injury

Confirm Nerve injury

Temporary or permanent?

- **Mechanism**
- **Duration**
- Identify the extent of injury
 - Size neuropathic area
 - Subjective function
 - Mechanosensory function
 - Disability
 - Pain / discomfort
 - Allodynia
 - Hyperalgesia
 - Spontaneous or elicited?



Patient's story and expectations?

Renton T, Thexton A, SJ Crean, Hankins M. Simplifying assessment of recovery of the lingual nerve from injury. BDJ 2006;10:569-573
Renton T, Thexton A, Mcgurk M. New method for the objective evaluation of injury to the lingual nerve after operation on third molars. Br J Oral Maxillofac Surg 2007; 49(2): 222-25. <http://www.bjoms.com/abstract.asp?doi=10.1055/s-0007-147000>

Assessment of neuropathic area

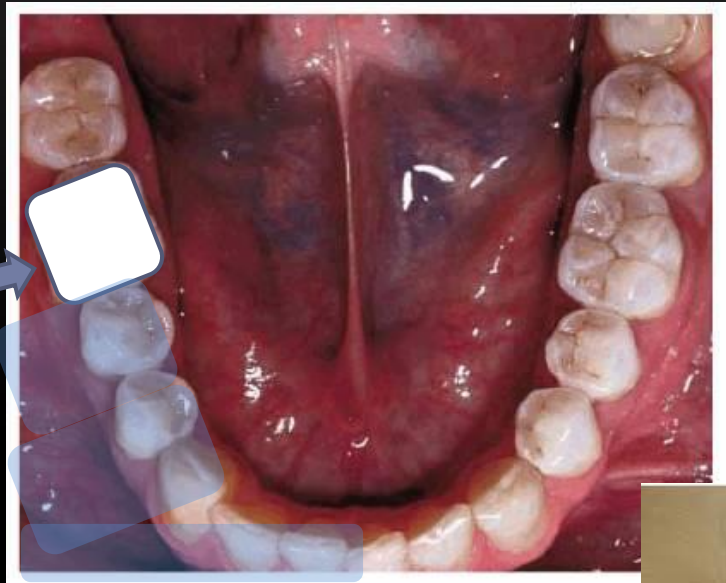Know your anatomy!

Implant extraction or endodontic procedure

undertaken with resultant numbness of mouth & lip with pain

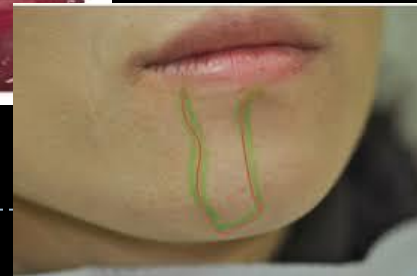Neuropathic area should affect 'DISTAL' domain of dermatome

In some cases only socket area can be affected with localised hypersensitivity



Neuropathic area you can use dental vitality tests but not very reliable

Extraoral area may be complete or partial
Below illustrates 40% affected

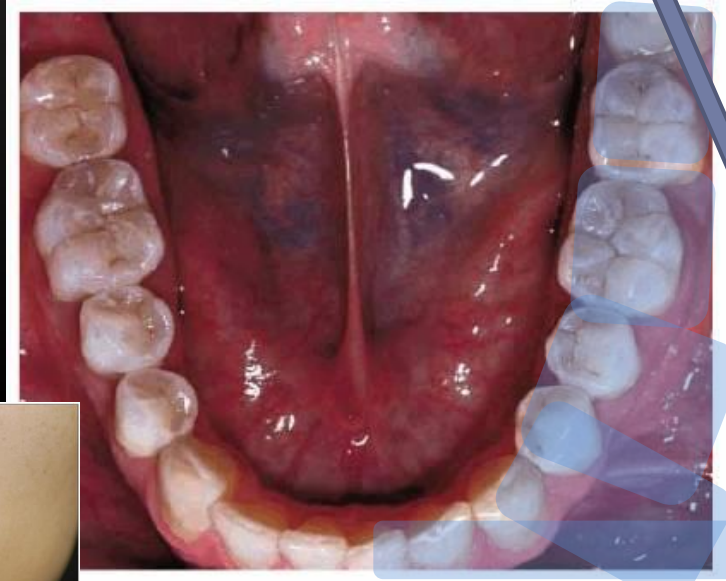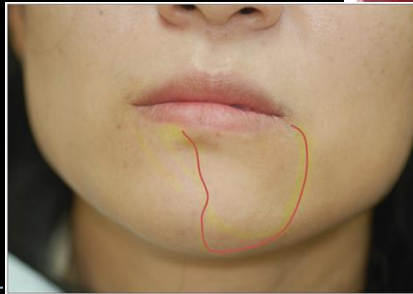


Assessment of neuropathic area

Know your anatomy!

Neuropathic area you can use dental vitality tests but not very reliable

Extraoral neuropathy affecting 9 of area0%



Inferior dental block undertaken with resultant numbness of mouth&lip with pain

Neuropathic area should affect 'DISTAL' domain of dermatome

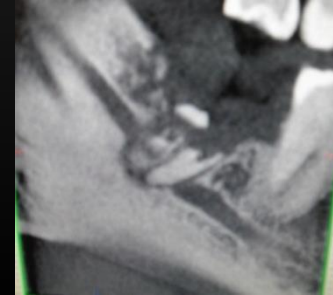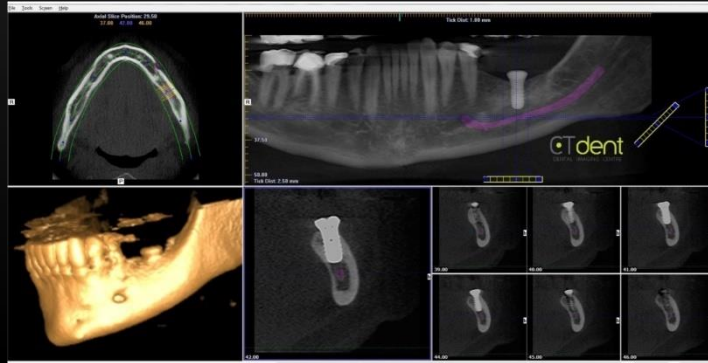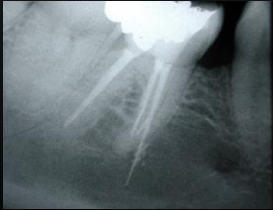


Assessment of nerve injury

Indication for investigations

Radiology Post surgical radiographs (panoral for wisdom teeth and LCPA for endo Nis) are required to confirm causality though mainly a clinical diagnosis

Post surgical CBCTs only required for M3M lingual and Inferior alveolar nerve injury



Use plain film only

CBCT -unnecessary irradiation of the patient

Provides no further information and does not change treatment



Management of dentistry related nerve injury

- Prevention is best!
- Treatment must depend upon the mechanism and duration of nerve injury
- Treat
 - Pain
 - Functional disability
 - Psychological impact
- Counselling
 - Reaffirm nerve injury is permanent
 - Be honest with the patient
 - Reassurance and explanation
- Medical for pain +/- depression
 - Topical
 - Systemic
- Surgical
- Remove implant within 30 hours

Int. J. Oral Maxillofac. Surg. 2012; 41: 629–637
doi:10.1016/j.ijom.2011.11.002, available online at <http://www.sciencedirect.com>

International Journal of
*Oral &
Maxillofacial
Surgery*

Review Paper
Oral Surgery

Managing iatrogenic trigeminal nerve injury: a case series and review of the literature

T. Renton, Z. Yilmaz
King's College London Dental Institute,
Denmark Hill Campus, London, UK

T. Renton, Z. Yilmaz: Managing iatrogenic trigeminal nerve injury: a case series and review of the literature. Int. J. Oral Maxillofac. Surg. 2012; 41: 629–637. © 2011 International Association of Oral and Maxillofacial Surgeons. Published by Elsevier Ltd. All rights reserved.

Abstract. This study describes the management of 216 patients with post-traumatic iatrogenic lingual nerve injuries (LNIs; $n = 93$) and inferior alveolar nerve injuries (IANI; $n = 123$). At initial consultation, 6% IANI and 2% LNI patients had undergone significant resolution requiring no further reviews. Reassurance and counselling was adequate management for 51% IANI and 55% LNI patients. Systemic or topical medication was offered as pain relief to 5% of patients. Additional cognitive behaviour therapy (CBT) was offered to 8% of patients. Topical 5% lidocaine patches reduced pain and allodynia in 7% of IANI patients, most often used without any other form of management. A small percentage of IANI patients (4%) received a combination of therapies involving CBT, surgery, medication and 5% lidocaine patches. Exploratory surgery improved symptoms and reduced neuropathic area in 18 LNI and 15 IANI patients resulting in improved quality of life. In conclusion, the authors suggest a more diverse and perhaps holistic strategy for management of patients with iatrogenic trigeminal nerve injuries and recommend pragmatic assessment criteria for measurement of treatment success in these patients.

Accepted for publication 8 November 2011
Available online 10 February 2012



Multidisciplinary management


Regardless of location of injury, NP is diagnosed based on common neurologic signs and symptoms that are revealed by history taking and on physical examination.

NP is best treated with a combination of multiple therapeutic approaches, which starts with patient education, and the treatments include conservative, complementary, medical, interventional, and surgical treatment modalities.

Goals of treatment include improvement in pain control and in coping skills as well as restoration of functional status. Early identification of realistic treatment expectations is the key to building a successful relationship with a patient suffering from NP.

In most instances when treating chronic NP, the approach to pain management begins with conservative therapies and advances to more interventional ones only when earlier modalities do not meet goals of pain relief and improved function, because risks increase with the invasiveness of the therapies. Most patients with NP benefit most from an individualized, multimodal approach that emphasizes both pain and function.



Managing Neuropathic Pain 

Robert Carter Wellford Jones III, MD, PhD^a, Erin Lawson, MD^{a,b}, Miroslav Backonja, MD^{c,*}

KEYWORDS

- Neuropathic pain • Neuralgia • Peripheral neuropathy • Radiculopathy
- Anticonvulsants • Interventional treatments • Physical therapy
- Cognitive behavioral therapy

KEY POINTS

- Neuropathic pain (NP) arises from injuries or diseases affecting the somatosensory component of the nervous system at any level of the peripheral nervous system or central nervous system (CNS).
- Regardless of location of injury, NP is diagnosed based on common neurologic signs and symptoms that are revealed by history taking and on physical examination.
- NP is best treated with a combination of multiple therapeutic approaches, which starts with patient education, and the treatments include conservative, complementary, medical, interventional, and surgical treatment modalities.
- Goals of treatment are the same as in pain management in general, and they include improvement in pain control and in coping skills as well as restoration of functional status. Early identification of realistic treatment expectations is the key to building a successful relationship with a patient suffering from NP.
- In most instances when treating chronic NP, the approach to pain management begins with conservative therapies and advances to more interventional ones only when earlier modalities do not meet goals of pain relief and improved function, because risks increase with the invasiveness of the therapies. Most patients with NP benefit most from an individualized, multimodal approach that emphasizes both pain and function.

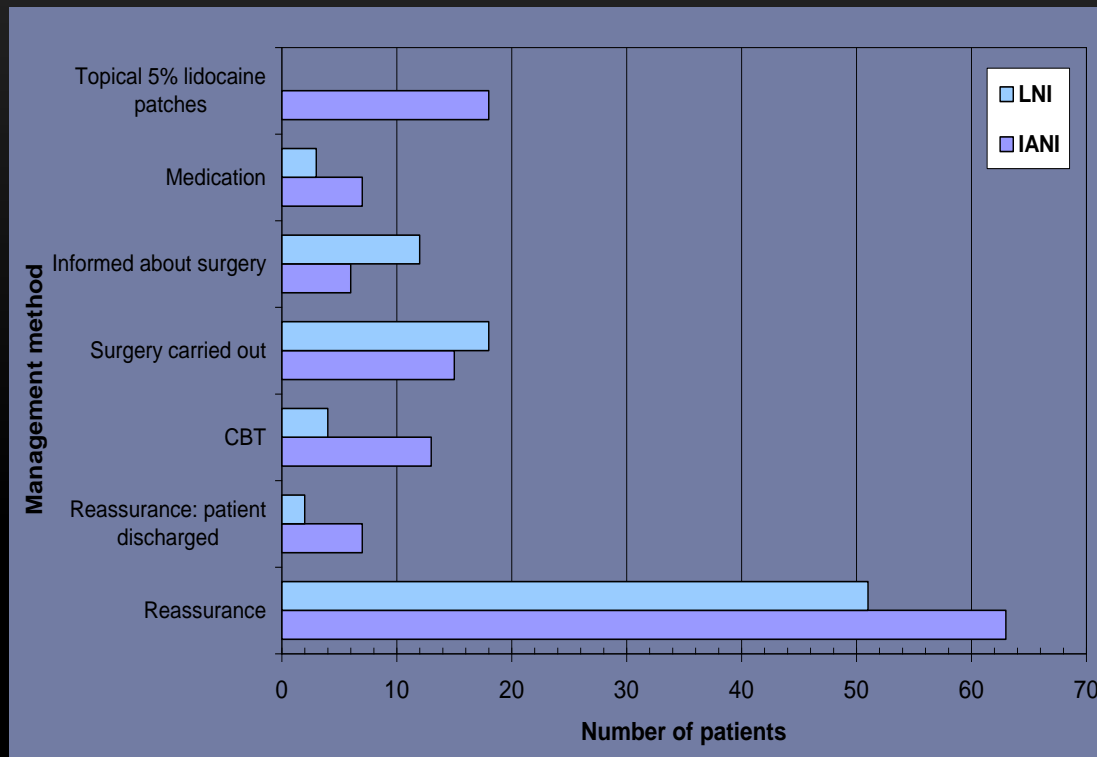


Main goal is to provide patient with a clear diagnosis

- ▶ Patient understanding of their condition and realistic expectations underpins their compliance with treatment and optimises outcomes (**psychological intervention**)
- ▶ Reassuring your patient that lessons have been learnt and prevention of future similar problems is being undertaken
- ▶ Maximise reversal of injury (**early surgical intervention**)
- ▶ Reducing pain where possible (**medical**)
- ▶ Improving functional status (**psychological intervention**)



Management of patients is often complex in attempting to reduce pain, improve function and remediate psychological sequelae

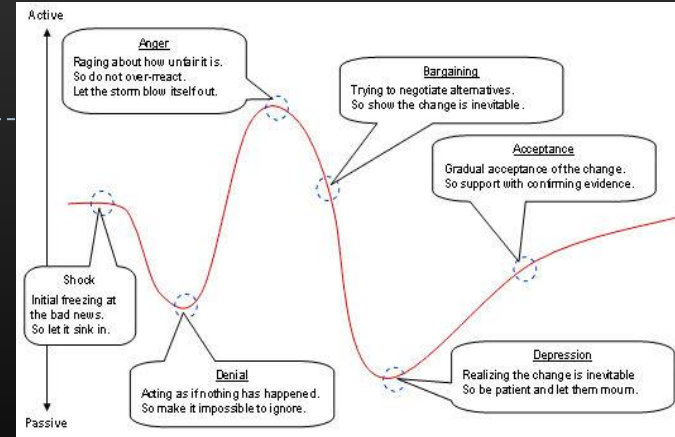


A small percentage of IANI patients (4%) received a combination of therapies involving CBT, surgery, medication and 5% lidocaine patches

Psychological interventions

- ▶ Management of existing mental health problems
- ▶ Cognitive behavioural therapy
- ▶ Mindfulness
- ▶ NLP

▶ Smith J et al Psychological morbidity of iatrogenic trigeminal nerve injuries Accepted J Orofacial pain August 2012 MPS annual report Dec 2011



8 The impact of error on the patient



Dr Lisa Page is a consultant psychiatrist to the Facial Pain Clinic at the King's Dental Institute in London where she has helped develop a unique multi-disciplinary approach to the management of trigeminal nerve injuries

What happens to a dental patient after a mistake?

Patients generally agree to dental treatment expecting a good outcome. Consequently they are often ill-prepared should an injury occur. When major mistakes happen, patients usually experience an initial period of disbelief and shock. For many there may be a protracted period before the extent of the injury is confirmed and it is not uncommon for the patient to be in denial during this stage. Initial

Management of dentistry related nerve injury

Depends upon duration and mechanism of injury

We cannot fix nerve injuries!

Wait for resolution

- Lingual nerve injuries related to LINGUAL ACCESS third molar surgery
- LA
- Trauma
- Orthognathic

Consent patient properly...forearmed is for warned

Risk assessment in planning

Check on patients post operatively HOME CHECK

Acknowledge problem

No sit and WAIT !!!!!

You MUST reassure your patient but don't give them false expectations!

---Seek advice- Trigeminalnerve.org.uk- Medication and REFERRAL

URGENT treatment < 30 hours

- ▶ Suspected nerve trauma
- ▶ Implants
- ▶ Endodontics

- ▶ **Within 2 weeks**
- ▶ Buccal approach Lingual nerve
- ▶ Inferior alveolar nerve injuries related to third molar surgery



Management principles of patient with PTNP

MANAGEMENT OF TRIGEMINAL NERVE INJURIES RELATED TO DENTAL PROCEDURES

Timeline	During surgery	Post surgery 2 -6 weeks	12 weeks	> 12 weeks	
Psychological intervention					
Medical intervention					
High risk nerve injury/ or patient high risk of developing neuropathic pain consider pre-emptive Amitriptyline or Pregabalin	Reported neuropathy immediate post-surgery <ul style="list-style-type: none"> NSAIDs Ibuprofen 6—mg TDS 5 days (MH permitting) step down Prednisolone 50-10mg over 5 days (exclude known risk of DU and or PU) Vitamin B complex (long term during recovery) 	If required: Psychological support (for PTSD and sleep disorders) and Therapeutic management of neuropathic pain (NICE Guidance Ne Pain in adults) <ul style="list-style-type: none"> Step 1 Amitriptyline or Nortriptyline Adjunctive topical agents (Lidocaine, Capsaicin) Step II Gabapentin or Pregabalin 			
Surgical intervention					
Known or suspected nerve Inferior alveolar or lingual injury Duty of candour inform patient immediately Repair nerve immediately Or refer for immediate repair to a specialist centre	Post Local anaesthesia or orthognathic surgery or trauma Duty of candour inform patient immediately Surgery not indicated Medical and psychological therapies	Post Implant or endodontic surgery Patient presents with nerve injury early postoperatively Confirm extensive dermatome affected, anaesthesia, +/- paraesthesia, +/- neuropathic pain Within 30 hours Remove implant or endodontically treated tooth and reassess patient combined with medical intervention above	Post M3M surgery Patient presents with nerve injury early postoperatively Confirm extensive dermatome affected, anaesthesia, +/- paraesthesia, +/- neuropathic pain Inferior alveolar nerve DPT confirms retained roots or bony defect of IDC Lingual nerve (buccal approach) DPT confirms retained roots CBCT confirms lingual plate defect due to M3M surgery Consider early exploration (IAN via M3M socket) +/- nerve repair dependent upon surgical findings	Patient presents with persistent non-resolving LINGUAL nerve injury after lingual access (lingual retraction +/- lingual split) surgery Confirm extensive dermatome affected, anaesthesia, +/- paraesthesia, +/- neuropathic pain Consider exploration @ 12 weeks +/- nerve repair dependent upon surgical findings	Patient presents with persistent non-resolving Inferior alveolar nerve injury OR LINGUAL nerve injury after M3M surgery Confirm extensive dermatome affected, anaesthesia, +/- paraesthesia, +/- neuropathic pain Consider medical and psychological therapeutic measures. N.B Surgical repair DOES NOT IMPROVE neuropathic pain

- *New developments*
- *MRI micro neurography may assist in confirmation of damage to IAN and LN (currently available in US under development London, Belgium).*
- *Larger IAN defects can be optimally repaired using Axogen cadaveric nerve graft (currently NICE approved for hand surgery in UK)*

Medical management of neuropathic pain



Management- Pain medication systemic

- ▶ **Neuralgic pain**
 - Oxcarbazepine
 - Neurontin (Lyrica) Pregabalin
 - Gabapentin
- ▶ **Burning chronic pain**
 - Nortriptyline > Amitriptyline
- ▶ 15% Pts persisted with systemic meds
- ▶ 18% IANI used topical medication



Medical management

- ▶ Drugs proposed as first line include. **tricyclic antidepressants (particularly amitriptyline), serotonin-norepinephrine reuptake inhibitors (particularly duloxetine), pregabalin and gabapentin**
- ▶ Second line treatments include **lidocaine plasters and capsaicin high concentration patches for peripheral neuropathic pain only**, and tramadol.
- ▶ Third line treatments include **strong opioids and botulinum toxin A** (for peripheral neuropathic pain).
- ▶ Perspectives include the development of new compounds and a more personalized therapeutic approach, which is made possible by recent progress in the assessment and understanding of neuropathic pain.



HHS Public Access

Author manuscript

Lancet Neurol. Author manuscript; available in PMC 2016 February 01.

Published in final edited form as:

Lancet Neurol. 2015 February ; 14(2): 162–173. doi:10.1016/S1474-4422(14)70251-0.

Pharmacotherapy for neuropathic pain in adults: systematic review, meta-analysis and updated NeuPSIG recommendations

Nanna B Finnerup, MD^{*,a}, Nadine Attal, MD^{*,b,c,1}, Simon Haroutounian, PhD^d, Ewan McNicol, MS^e, Ralf Baron, MD^f, Robert H Dworkin, PhD^g, Ian Gilron, MD^h, Maija Haanpaa, MDⁱ, Per Hansson, MD^j, Troels S Jensen, MD^{a,k}, Peter R Kamerman, PhD^l, Karen Lund, MD^a, Andrew Moore, DSc^m, Srinivasa N Raja, MDⁿ, Andrew SC Rice, MD^o, Michael Rowbotham, MD^p, Emily Sena, PhD^q, Philip Siddall, MD^r, Blair H Smith, MD^s, and Mark Wallace, MD^t

¹Corresponding author: Nadine ATTAL, INSERM U 987 and Centre d'Evaluation et de Traitement de La Douleur, Hospital Ambroise Pare, Boulogne-Billancourt, France Tel.: 0033149094433 ; nadine.attal@apr.aphp.fr.

²N Attal and NB Finnerup contributed equally to this work.

Conflicts of interest

NA has served on the advisory boards or speakers panels of Astellas Pharma, Adir Servier, Eli Lilly, Grunenthal, Johnson and Johnson, Sanofi Pasteur Merieux and Pfizer and has been investigator of studies sponsored by Astellas, Grunenthal and Astra Zeneca. RB has received grant/research support from Pfizer, Genzyme, Grunenthal, German Federal Ministry of Education and Research

Attal N. Pharmacological treatments of neuropathic pain: The latest recommendations. *Rev Neurol (Paris)*. 2018 Oct 11. pii: S0035-3787(18)30727-6. doi: 10.1016/j.neurol.2018.08.005.

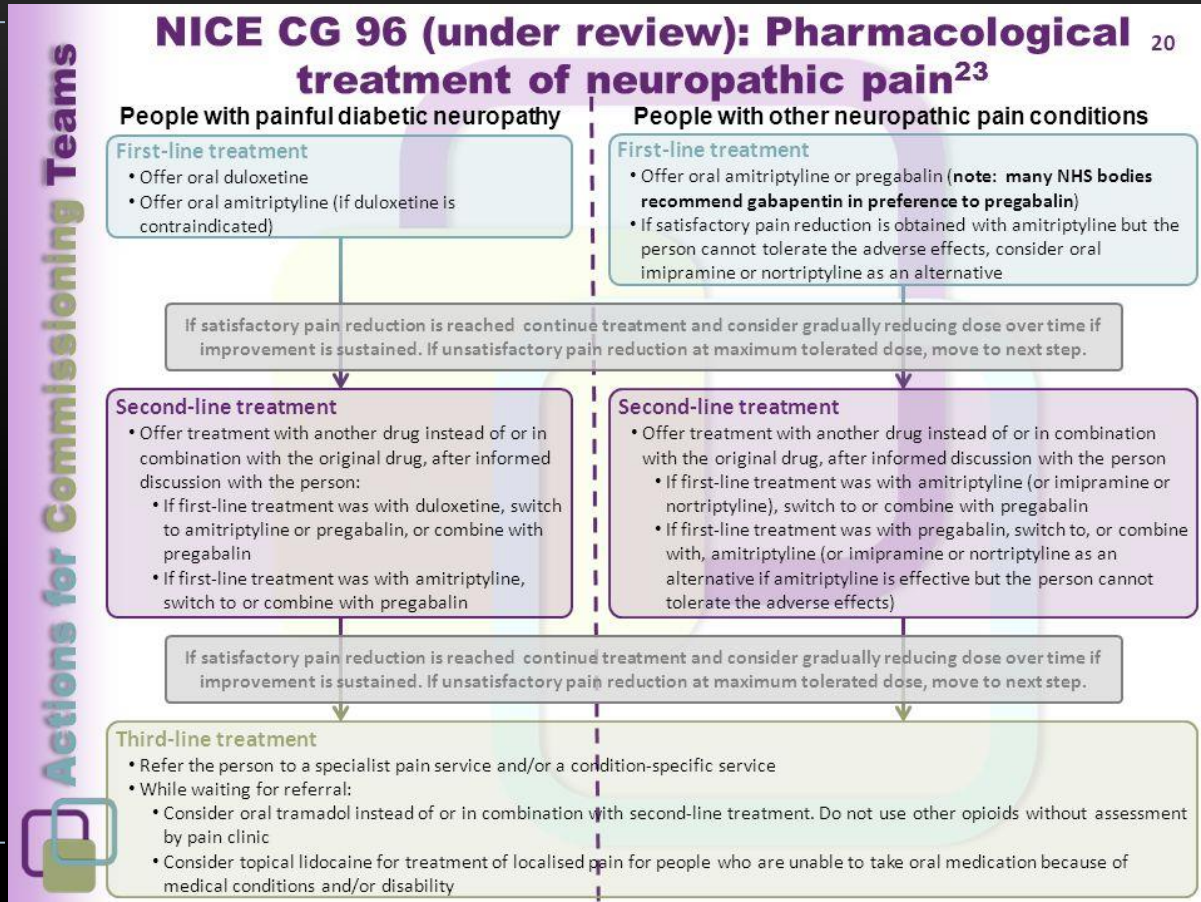
American Society Neurology Medical Management

▶ Medical management of neuropathic pain

TABLE 5. Level A and level B recommendations from the American Academy of Neurology for the treatment of painful diabetic neuropathy¹⁵

	Recommended drugs and doses and other treatments	Drugs and other treatments not recommended
Level A	Pregabalin, 300–600 mg/d	Oxcarbazepine
Level B	<ul style="list-style-type: none"> • Gabapentin, 900–3600 mg/d • Sodium valproate, 500–1200 mg/d • Venlafaxine, 75–225 mg/d • Duloxetine, 60–120 mg/d • Amitriptyline, 25–100 mg/d • Dextromethorphan, 400 mg/d • Morphine sulfate, titrated to 120 mg/d • Tramadol, 210 mg/d • Oxycodone, mean of 37 mg/d, maximum of 120 mg/d • Capsaicin cream, 0.075% 4 times daily • Isosorbide dinitrate spray • Electrical stimulation, percutaneous nerve stimulation, 3–4 wk 	<ul style="list-style-type: none"> • Lamotrigine • Lacosamide • Clonidine • Pentoxifylline • Mexiletine • Magnetic field treatment • Low-intensity laser therapy • Reiki therapy

National Institute Clinical excellence (NICE) NHS Guidance for prescribing for adult neuropathic pain



Capsaicin patches

Pharmacology

Original Paper

Pharmacology 2018;101:290-297
DOI: 10.1159/000487444

Received: November 28, 2017
Accepted after revision: January 16, 2018
Published online: March 27, 2018

Efficacy Analysis of Capsaicin 8% Patch in Neuropathic Peripheral Pain Treatment

Joana Tenreiro Pinto^a Frederico C. Pereira^{b,c} Maria C. Loureiro^a
Ricardo Gama^d Hugo L. Fernandes^e

^aDepartment of Anesthesiology, Centro Hospitalar Tondela, Viseu, Portugal; ^bLaboratory of Pharmacology and Experimental Therapeutics/Institute for Biomedical Imaging and Life Sciences (IBILI), Faculty of Medicine, University of Coimbra, Coimbra, Portugal; ^cCenter of Neuroscience and Cell Biology (CNC) and CNC/IBILI Research Consortium, University of Coimbra, Coimbra, Portugal; ^dSchool of Technology and Management of Lamego, Polytechnic Institute of Viseu, Viseu, Portugal; ^eDepartment of Physical Medicine and Rehabilitation, Northwestern University, Sensory Motor Performance Program, Rehabilitation Institute of Chicago, Chicago, IL, USA

Keywords

Capsaicin · Allodynia · Analgesic effect · Peripheral neuropathic pain

Abstract

Background/Aims: Several guidelines for neuropathic pain management and various effective drugs are available; however, neuropathic pain remains undertreated. This retrospective study aimed to evaluate the efficacy of topical capsaicin 8% in peripheral neuropathic pain in a routine clinical setting. **Methods:** Therapeutic efficacy was evaluated through pain intensity, using numerical pain rating scale at baseline and 7–14 days after each treatment, and using pain treatment area (PTA) assessed immediately before each treatment. **Results:** A total of 43 patients with either post-herpetic neuralgia or post-traumatic/post-surgical neuropathic pain were enrolled. The median percentage reduc-

tion in numerical pain rating scale score and in PTA was –40.0 (–50.0 to –33.3; 95% CI, bootstrap) and –35.1 (–50.9 to 3.4; 95% CI, bootstrap), respectively. Pain intensity and PTA were equally improved and reduced in both treated conditions. **Conclusion:** This study suggests that topical capsaicin 8% reduces peripheral neuropathic pain as well as treatment pain area.

© 2018 S. Karger AG, Basel

Introduction

Peripheral neuropathic pain is defined as pain caused by a lesion or disease affecting the peripheral somatosensory system [1]. Post-traumatic and postoperative nerve injuries represent a frequent cause of peripheral neuropathic pain. Localized neuropathic pain is a type of neuropathic pain that is characterized by consistent

RESEARCH ARTICLE

Open Access



Effectiveness of the capsaicin 8% patch in the management of peripheral neuropathic pain in European clinical practice: the ASCEND study

Colette Mankowski¹, Chris D. Poole¹, Etienne Ernault^{2*}, Roger Thomas³, Ellen Berni¹, Craig J. Currie⁴, Cecil Treadwell¹, José I. Calvo⁵, Christina Plastrá⁶, Eirini Zafeiropoulou⁶ and Isaac Odeyemi¹

Abstract

Background: In randomised studies, the capsaicin 8% patch has demonstrated effective pain relief in patients with peripheral neuropathic pain (PNP) arising from different aetiologies.

Methods: ASCEND was an open-label, non-interventional study of patients with non-diabetes-related PNP who received capsaicin 8% patch treatment, according to usual clinical practice, and were followed for ≤52 weeks. Co-primary endpoints were percentage change in the mean numeric pain rating scale (NPRS) 'average daily pain' score from baseline to the average of Weeks 2 and 8 following first treatment; and median time from first to second treatment. The primary analysis was intended to assess analgesic equivalence between post-herpetic neuralgia (PHN) and other PNP aetiologies. Health-related quality of life (HRQoL, using EQ-5D), Patient Global Impression of Change (PGIC) and tolerability were also assessed.

Results: Following first application, patients experienced a 26.6% (95% CI: 23.6, 29.62; $n = 412$) reduction in mean NPRS score from baseline to Weeks 2 and 8. Equivalence was demonstrated between PHN and the neuropathic back pain, post-operative and post-traumatic neuropathic pain and 'other' PNP aetiology subgroups. The median time from first to second treatment was 191 days (95% CI: 147, 235; $n = 181$). Forty-four percent of all patients were responders (≥30% reduction in NPRS score from baseline to Weeks 2 and 8) following first treatment, and 86.9% ($n = 159/183$) remained so at Week 12. A sustained pain response was observed until Week 52, with a 37.0% (95% CI: 31.3, 42.7; $n = 176$) reduction in mean NPRS score from baseline. Patients with the shortest duration of pain (0–0.72 years) experienced the highest pain response from baseline to Weeks 2 and 8. Mean EQ-5D index score improved by 0.199 utils (responders: 0.292 utils) from baseline to Week 2 and was maintained until Week 52. Most patients reported improvements in PGIC at Week 2 and at all follow-up assessments regardless of number of treatments received. Adverse events were primarily mild or moderate reversible application site reactions.

Conclusion: In European clinical practice, the capsaicin 8% patch provided effective and sustained pain relief, substantially improved HRQoL, improved overall health status and was generally well tolerated in a heterogeneous PNP population.

KING'S
College
LONDON

Botoxin A

- ▶ A literature review was conducted using The Cochrane Controlled Trials Register, Medline and EMBASE databases limited to English Language articles published from 1980 to 2012.
- ▶ There is level 1 evidence supporting the efficacy of Botox in the treatment of spasmodic dysphonia, essential voice tremor, headache, cervical dystonia, masticatory myalgia, sialorrhoea, temporomandibular joint disorders, bruxism, blepharospasm, hemifacial spasm and rhinitis. For chronic neck pain there is level 1 evidence to show that Botox is ineffective.
- ▶ Level 2 evidence exists for vocal tics, trigeminal neuralgia, dysphagia and post-laryngectomy oesophageal speech.
- ▶ Level 4 for stuttering, 'first bite syndrome', facial nerve paresis, Frey's syndrome, oromandibular dystonia and palatal/stapedial myoclonus



REVIEW

The therapeutic usage of botulinum toxin (Botox) in non-cosmetic head and neck conditions – An evidence based review



Kamran Habib Awan*

Department of Oral Medicine & Diagnostic Sciences, College of Dentistry, King Saud University, Riyadh, Saudi Arabia

Received 7 November 2015; accepted 24 April 2016

Available online 30 April 2016

KEYWORDS

Botox;
Level of evidence;
Head and neck;
Review;
Toxin

Abstract Botulinum toxin (Botox) is an exotoxin produced from *Clostridium botulinum*. It blocks the release of acetylcholine from the cholinergic nerve end plates resulting in inactivity of the muscles or glands innervated. The efficacy of Botox in facial aesthetics is well established; however, recent literature has highlighted its utilization in multiple non-cosmetic medical and surgical conditions. The present article reviews the current evidence pertaining to Botox use in the non-cosmetic head and neck conditions. A literature search was conducted using MEDLINE, EMBASE, ISI Web of Science and the Cochrane databases limited to English Language articles published from January 1980 to December 2014. The findings showed that there is level 1 evidence supporting the efficacy of Botox in the treatment of laryngeal dystonia, headache, cervical dystonia, masticatory myalgia, sialorrhoea, temporomandibular joint disorders, bruxism, blepharospasm, hemifacial spasm and rhinitis. For chronic neck pain there is level 1 evidence to show that Botox is ineffective. Level 2 evidence exists for vocal tics and trigeminal. For stuttering, facial nerve paresis, Frey's syndrome and oromandibular dystonia the evidence is level 4. Thus, there is compelling evidence in the published literature to demonstrate the beneficial role of Botox in a wide range of non-cosmetic conditions pertaining to the head and neck (mainly level 1 evidence). With more and more research, the range of clinical applications and number of individuals getting Botox will doubtlessly increase. Botox appears to justify its title as 'the poison that heals'.

© 2016 The Author. Production and hosting by Elsevier B.V. on behalf of King Saud University. This is an open access article under the CC BY-NC-ND license (<http://creativecommons.org/licenses/by-nc-nd/4.0/>).

Patil S, Willett O, Thompkins T, Hermann R, Ramanathan S, Cornett EM, Fox CJ, Kaye AD. Botulinum Toxin: Pharmacology and Therapeutic Roles in Pain States. *Curr Pain Headache Rep*. 2016 Mar;20(3):15. doi: 10.1007/s11916-016-0545-0.

Persaud R, Garaş G, Silva S, Stamatoglou C, Chatrath P, Patel K. An evidence-based review of botulinum toxin (Botox) applications in non-cosmetic head and neck conditions. *JRSM Short Rep*. 2013 Feb;4(2):10. doi: 10.1177/2042533312472115. Epub 2013 Feb 12.

Botoxin A

Burmeister et al. *Trials* (2015) 16:550
DOI 10.1186/s13063-015-1052-z



STUDY PROTOCOL

Open Access



Botulinum neurotoxin type A in the treatment of classical Trigeminal Neuralgia (BoTN): study protocol for a randomized controlled trial

Jan Burmeister^{1*}, Dagny Holle¹, Eva Bock², Claudia Ose², Hans-Christoph Diener¹ and Mark Obermann¹

Abstract

Background: Trigeminal neuralgia is characterized by paroxysmal facial pain attacks. Adequate prophylactic drug therapy is often limited by the lack of efficacy and intolerance due to central nervous system side effects. Subcutaneous injections of botulinum toxin type A are a promising treatment option for patients with unsatisfactory response to drug therapy or neurosurgical intervention. Its effects are expected to last for at least 3 months, so it could be a potential long-term treatment.

This is the study protocol of a prospective, placebo-controlled, double blind clinical trial investigating the add-on therapy of subcutaneous administration of botulinum toxin type A injections to standard treatment in therapy-refractory classical trigeminal neuralgia.

Methods and design: BoTN is a prospective, double blind, placebo-controlled trial with a randomized withdrawal design in which a single blind phase is followed by a double blind phase (see also Methods and design). Eligible patients with classical trigeminal neuralgia who are otherwise refractory to medical and neurosurgical treatment will receive subcutaneous injections of botulinum toxin type A into injection sites of the affected trigeminal branch. In the first phase all patients will receive botulinum toxin type A in a single blinded intervention. Twelve weeks later therapy responders will be allocated to the *verum* or placebo (saline) arm in a double blind, randomized manner. These injections will be performed at the same sites as the first injections. This trial will be conducted in a tertiary outpatient clinic specialized in the treatment of headache and facial pain. There will be three investigators performing the injections who are experienced in the treatment of headache and facial pain and trained in botulinum toxin type A injections.

Discussion: BoTN is designed to assess the efficacy and safety of subcutaneous botulinum toxin type A injections in addition to standard prophylactic treatment in therapy-refractory trigeminal neuralgia.

Trial registration number: EU Clinical Trials Register: EudraCT-No: 2014-001959-24 <https://www.clinicaltrialsregister.eu/ctr-search/rest/download/trial/2014-001959-24/DE>
Date of trial registration
26 August 2014

Keywords: Trigeminal neuralgia, Botulinum toxin type A, Prophylactic treatment, Clinical trial, Prospective study, Study protocol

The efficacy of botulinum toxin for the treatment of trigeminal and postherpetic neuralgia: a systematic review with meta-analyses

Thomas Shackleton, DDS, MS,^a Saravanan Ram, DDS, MS,^b Misty Black, DDS, MS,^c Jon Ryder, DDS, MS,^d Glenn T. Clark, DDS, MS,^e and Reyes Enciso, PhD^f

Objective. To evaluate the efficacy of a botulinum toxin type A (BoTN-A) in treating trigeminal neuralgia (TN) and postherpetic neuralgia (PHN).

Study Design. Three databases were searched: Medline, Web of Science, and Cochrane Library. The search was restricted to English-language randomized, placebo-controlled trials. Three review authors evaluated the cases for risk of bias.

Results. Six studies were eligible for inclusion. Pooled results showed a difference in post-treatment pain intensity of -3.009 (95% confidence interval -4.566 to -1.453 ; $P < .001$) in favor of BoTN-A compared with placebo in managing TN or PHN. Of the six studies, five had unclear risk of bias, and one showed high risk.

Conclusions. Although the studies had unclear or high risk of bias, moderate evidence regarding the efficacy of BoTN-A in treating TN and PHN was found. BoTN-A might be an alternative treatment to those patients who are either unable to manage their pain medically or would like adjunct therapy. (Oral Surg Oral Med Oral Pathol Oral Radiol 2016;122:61-71)

Neuralgia is described as pain extending along the course of one or more nerves. Many varieties of neuralgia are distinguished according to the nerves affected, such as the trigeminal, brachial, occipital, and supraorbital nerves, or to the cause, such as postherpetic, anemic, diabetic, gouty, malarial, or syphilitic factors.¹ Pain from neuralgias is often debilitating to those who suffer from it. These patients often suffer for extended periods before any sort of beneficial therapy is suggested.² There are two major treatment strategies for neuralgias: pharmacotherapy and neurosurgery. Medical management is the mainstay treatment for most neuralgias, since it generally carries a lower risk compared with major surgical procedures and is suitable for medically compromised patients who are unfit for such surgery.³ However, side effects from systemic medications, such as ataxia, dizziness, nausea, fatigue, rash, and somnolence, can be problematic and debilitating.

Botulinum toxin type A (BoTN-A) is a potent neurotoxin that blocks acetylcholine release from presynaptic nerve endings by interfering with the

activity of SNARE (soluble N-ethylmaleimide-sensitive-factor attachment protein receptors) proteins. BoTN-A has been reported to have analgesic effects independent of its action on muscle tone.⁴ The most significant results have been observed in patients with neuropathic pain. Neuropathic pain caused by peripheral lesions has been the most widely studied. BoTN-A has shown its efficacy on pain and allodynia in various animal models of inflammatory neuropathic pain.⁵ The objective of this review was to determine the efficacy of BoTN-A when used as a treatment in patients suffering from trigeminal neuralgia (TN) or postherpetic neuralgia (PHN).

MATERIALS AND METHODS

This systematic review followed the recommendations of the Preferred Reporting Items for Systematic Reviews and Meta-analyses (PRISMA) statement.⁶

Eligibility criteria

Studies were limited to randomized controlled trials (RCTs) on the efficacy of BoTN-A compared with

Statement of Clinical Relevance

In this systematic review, the number of eligible studies was small, and the authors found unclear or high risk of bias in the included studies. However, moderate evidence regarding the efficacy of botulinum toxin A was found in treating trigeminal and postherpetic neuralgia as a treatment; this evidence provides hope that this may be an alternative treatment for those patients who are either unable to manage their pain medically or would like an adjunct therapy.

REVIEW ARTICLE

Open Access



Therapeutic efficacy and safety of Botulinum Toxin A Therapy in Trigeminal Neuralgia: a systematic review and meta-analysis of randomized controlled trials

Mostafa Ebraheem Morra^{1†}, Ahmed Elgebal^{1†}, Ahmed Elmarazy^{1†}, Adham M. Khalil^{2†}, Ahmed M. A. Altib³, Tran Le-Huy Vu⁴, Mostafa Reda Mostafa⁵, Nguyen Tien Huy^{6,7} and Kenji Hirayama^{8*}

Abstract

Background: Several different interventions have been examined to alleviate pain and reduce frequency of trigeminal neuralgia (TN) paroxysms. However, some patients continue to have persistent or recurrent painful attacks. Using a systematic review and meta-analysis approach, we aimed to synthesize evidence from published randomized controlled trials (RCTs) regarding safety and efficacy of botulinum toxin type A (BTX-A) as a possible emerging choice of treatment for TN.

Methods: We conducted an electronic search in 10 databases/electronic search engines to access relevant publications. All articles in all languages reporting RCTs on the efficacy and safety of BTX-A in the treatment of TN were included for systematic review and meta-analysis.

Results: A total of four RCTs (n = 178) were identified for final meta-analysis. The overall effect favored BTX-A versus placebo in terms of proportion of responders (risk ratio RR = 2.87, 95 % confidence interval CI [1.76, 4.69], p < 0.0001) with no significant detected heterogeneity (p = 0.31; I² = 4 %). Paroxysms frequency per day was significantly lower for BTX-A group (mean difference MD = -29.79, 95 % CI [-38.50, -21.08], p < 0.00001) with no significant heterogeneity (p = 0.21; I² = 36 %).

Conclusion: Despite limited data, our results suggest that BTX-A may be an effective and safe treatment option for patients with TN. Further larger and well-designed RCTs are encouraged to translate these findings into better clinical outcome and better quality of life for TN patients.

Keywords: Botulinum, BTX-A, Trigeminal neuralgia, Clinical trials, Systematic review, Meta-analysis

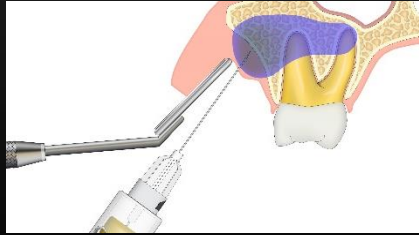Pre Botox LA injections for focal neuropathic pain

~~Lidocaine 2% (1:80K epinephrine) 1-2mls infiltrations~~-----

positive response prerequisite for BTX treatment but not predictive

PDAP I or primary localised intra oral Ne Pain

- ▶ 7 patients
- ▶ Mean age 55yrs
- ▶ 60% Female
- ▶ Site
 - 40% mandibular posterior molar region
 - 40% posterior maxillary molar region
 - 20% anterior maxilla



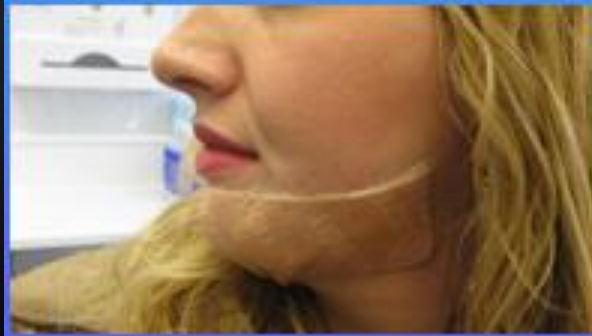- ▶ Response rate
 - ▶ Complete 3 (1 hour-30days)
 - ▶ Partial 2
 - ▶ None 2

PPTTN localised intra oral Ne Pain

- ▶ 18 patients
- ▶ Mean age 42 yrs
- ▶ 75% female
- ▶ Site
 - 15% mandibular posterior molar region
 - 5% posterior maxillary molar region
 - 80% anterior maxilla

- ▶ Response rate
 - ▶ Complete 14 (duration 1 hour -42 days)
 - ▶ Partial 2
 - ▶ None 2

Medical Management- topical 5% Lidocaine Versatis patches



- ▶ Excellent in minimising elicited pain due to:
- ▶ Cold allodynia caused by sport and winter activity
- ▶ Mechanical allodynia interfering sleep



Original Article



Case studies illustrating the management of trigeminal neuropathic pain using topical 5% lidocaine plasters

British Journal of Pain
7(2) 107-113
© The British Pain Society 2013
Reprints and permissions:
sagepub.co.uk/
journalsPermissions.nav
DOI: 10.1177/2046463713506349
bjp.sagepub.com
SAGE

Nadine Khawaja, Zehra Yilmaz and Tara Renton

Abstract

Chronic trigeminal pain, with its severe related functional problems, is difficult to treat. Treatment is often empirically based on medications used for other chronic pain conditions. Systemic sodium channel and calcium channel blocking agents may cause a multitude of complications that are often poorly tolerated by the patient.

Aims: The aim of this case report was to assess the efficacy of topical 5% lidocaine plasters in reducing pain and reducing adjuvant medication in patients with orofacial neuropathic pain.

Method: Fourteen patients with chronic orofacial pain conditions referred to the oral surgery department were instructed to wear 5% lidocaine plasters for 12 hours each day over the painful area. The conditions included post-surgical neuropathy ($n = 10$), multiple sclerosis-related pain ($n = 1$), persistent idiopathic facial pain ($n = 1$), Ramsay Hunt syndrome (post-herpetic neuralgia, $n = 1$) and trigeminal neuralgia ($n = 1$). Data were collected on patient demographics, pain levels and medication.

Results: Pain levels improved in 12 out of 14 patients. Nine patients had a reduction in adjuvant medication, two of whom completely stopped adjuvant treatment.

Conclusion: This case series demonstrates that of the use of 5% lidocaine plasters may play a useful role in the management of chronic trigeminal pain. A suggested novel approach for the management of orofacial pain, for clinicians, is presented.

Summary points

1. Management of chronic orofacial pain continues to be a major challenge to the clinician.
2. Patients are often placed on a multitude of medications in an attempt to alleviate pain without success.
3. Topical 5% lidocaine plasters, currently used for the management of post-herpetic neuralgia, offer the option of locally targeting trigeminal pain without the multiple side-effects of systemic medication.
4. This case series demonstrates that lidocaine plasters decrease verbal pain scores in extraoral, trigeminal and neuropathic pain, and reduce the use of other neuromodulatory agents in some, but not all, patients.
5. The plasters should be considered as a useful adjuvant in the management of pain in these patients.

Keywords

Chronic, lidocaine, neuropathic, pain, topical, trigeminal

Introduction

Chronic orofacial pain is comparable with other pain conditions in the body, accounting for between 20% and 25% of chronic pain conditions.¹ A recent cluster analysis classifying orofacial pain identifies neuralgia as

Department of Oral Surgery, King's College London, London, UK

Corresponding author:

Nadine Khawaja, Department of Oral Surgery, King's College London, King's College Dental Institute, Bessmer Road, London, SE5 8RS, UK.
Email: nadine.khawaja@kcl.ac.uk

Surgical management



Mini Review

Open Access

Managing post-traumatic trigeminal neuropathic pain: is surgery enough?

John R. Zuniga¹, Tara F. Renton²

¹Departments of Surgery and Neurology and Neurotherapeutics, The University of Texas Southwestern Medical Center at Dallas, Dallas, Texas, USA
²Department of Oral Surgery, Kings College London Dental Institute, Denmark Hill Campus, London SE5 9RS, UK

Article Info

Article Notes

Received: September 19, 2016
Accepted: October 08, 2016

*Correspondence:

John R. Zuniga DMD, MS, PhD, Departments of Surgery and Neurology and Neurotherapeutics, The University of Texas Southwestern Medical Center at Dallas, Dallas, Texas, USA.
Email: John.Zuniga@UTSouthwestern.edu

© 2016 Zuniga JR. This article is distributed under the terms of the Creative Commons Attribution 4.0 International License

Keywords:

Trigeminal Nerve
Neuropathic Pain
Trigeminal Nerve Microsurgery

ABSTRACT

In the absence of effective non-surgical methods to permanently resolve neuropathic pain involving the lip, chin, or tongue following inferior alveolar and/or lingual nerve injury, microsurgery of these nerves has been a recommended modality. In two ambispective clinical trials, we demonstrated that phenotypic differences exist between individuals with neuropathic pain and those without neuropathic pain of the trigeminal nerve. In those without neuropathic pain before microsurgery there was a 2% incidence of neuropathic pain after microsurgery whereas there was a 67% incidence of neuropathic pain after microsurgery, some reporting an increase in pain levels, when neuropathic pain was present before microsurgery. The recurrence of neuropathic pain after trigeminal microsurgery is likely multifactorial and might not depend on factors that normally affect useful or functional sensory recovery in those who have no neuropathic pain. These results indicate that the understanding of post-traumatic trigeminal neuropathic pain is incomplete. Predictive outcomes of treatment will probably improve when the etiology is better defined to allow mechanistic or target/site-specific treatment. Until then, non-surgical treatment for post-traumatic trigeminal neuropathic pain remains a safer option. Risk factors have been identified for patients developing chronic post-surgical pain due to post-traumatic neuropathy. These include psychological, medical, and age related factors. The best management may lie in preoperative screening and avoidance of elective surgery for high risk patients as the prevention of post-traumatic trigeminal neuropathic pain in the absence of effective medical or surgical interventions.

Surgical Repair of Trigeminal Nerve Injuries

Ahmad Alshadwi and Mohammed Nadershah

Additional information is available at the end of the chapter

<http://dx.doi.org/10.5772/64059>

Abstract

This chapter reviews the relevant surgical anatomy, clinical indications, and timing for surgical repair of the inferior alveolar and lingual nerve injuries. It will also present state-of-the-art reconstructive surgery and examine the factors influencing success as well as the scientific literature for outcome studies after surgical repair.

Keywords: trigeminal nerve, injury, surgical repair, microneurosurgery, nerve graft

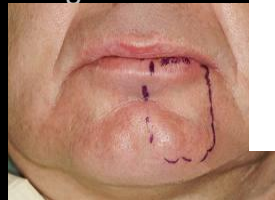1. Introduction

The trigeminal nerve and its peripheral branches are susceptible to injury from a wide variety of surgical procedures, trauma, and iatrogenic causes in the practice of dentistry and medicine. These types of injuries may result in significant morbidity due to their impact on speech, mastication, and social interactions. Although these sensory disturbances often recover spontaneously, some may be permanent with varying outcomes ranging from mild hypoesthesia to complete anesthesia. Some patients can also develop troublesome outcomes such as

Early postoperative detection of NI

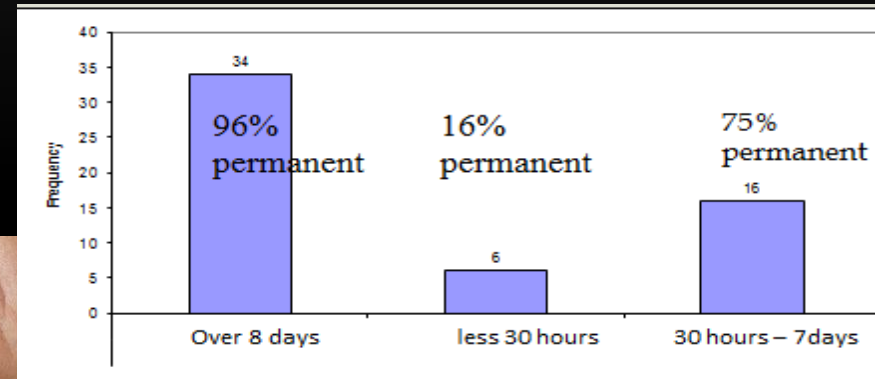
Early intervention after nerve injury can improve resolution?

- ▶ Acute management < 30 hours
 - ▶ (LA IDB lasts 3 hours and 25 minutes)
 - ▶ Check on Patient after 6 hours (Home check)
- ▶ IAN NEUROPATHY? (extreme pain/ mixed symptoms large neuropathic area)
 - ▶ Yes
 - ▶ Consult patient, check for area of neuropathy and signs of nerve injury
 - ▶ Confirmed
 - ▶ **Remove implant < 30 hours**
- ▶ + High dose oral NSAIDs (600-800mgs Ibuprofen PO QDS)
- ▶ Prednisolone 5 day step down does 50-40-30-20-10mg PO
 - ▶ Vitamin B Complex?
 - ▶ (check medical history!)
 - ▶ Review



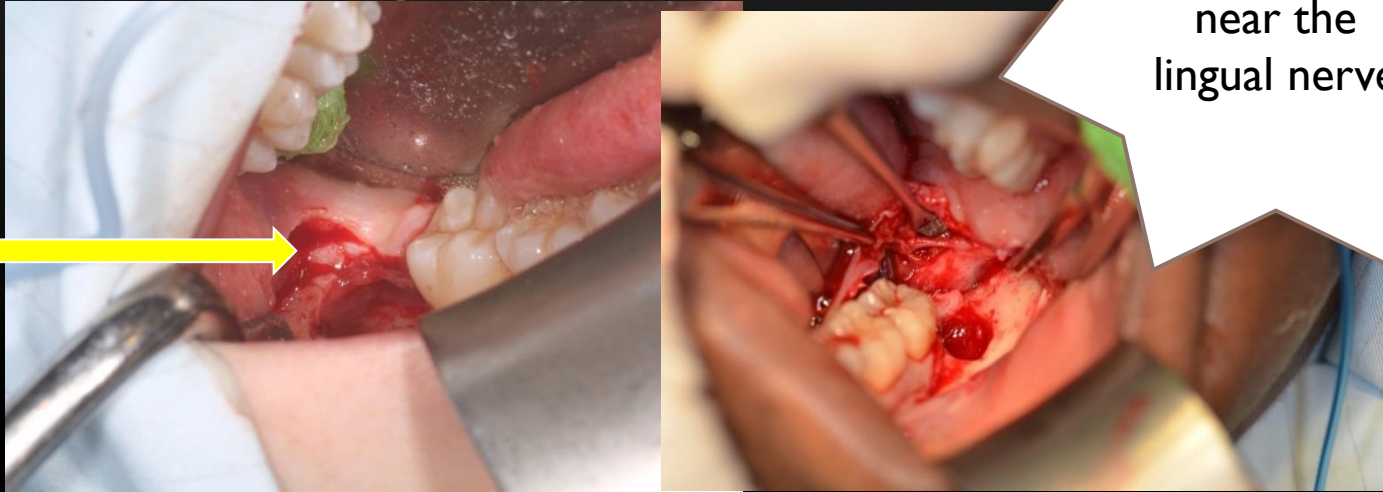
Only use plain films

Removing implant or endo filled tooth < 30 hours does Improve NI resolution
Review patient



Prevention LNI related to M3M surgery

Spot the lingual nerve!



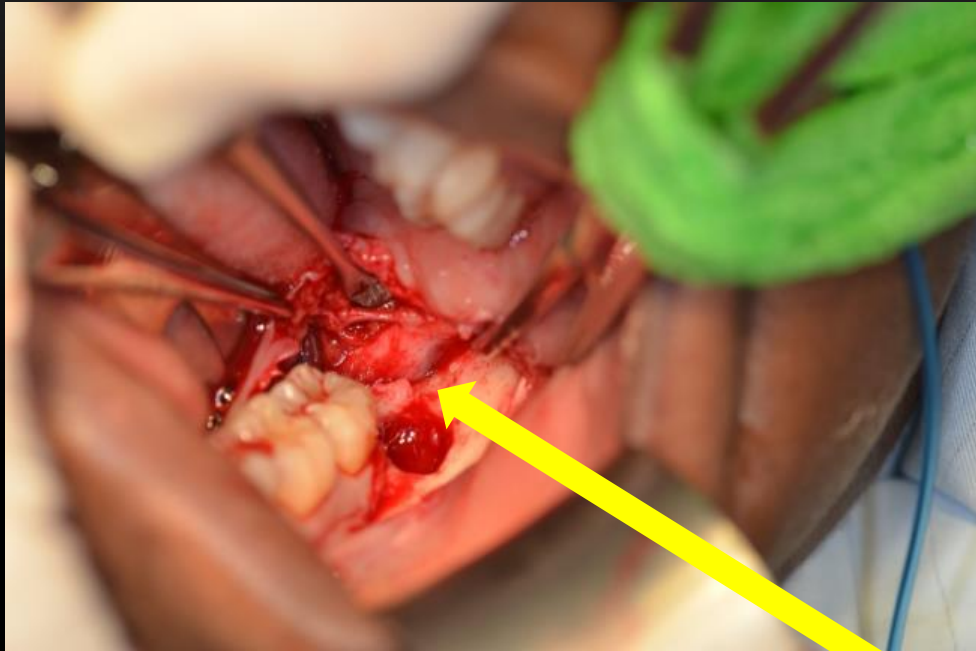
Avoid going
anywhere
near the
lingual nerve

Findings @ Lingual nerve exploration



Findings during lingual nerve exploration

.....we can see damaged lingual plates



Damaged Lingual plate can be detected by CBCT scanning early post surgically

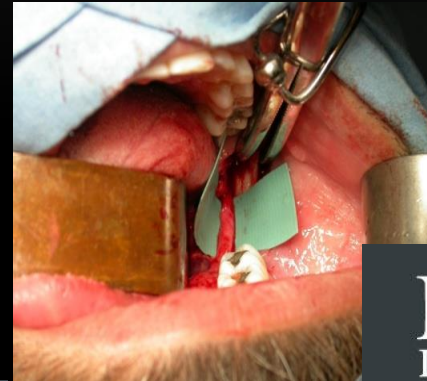
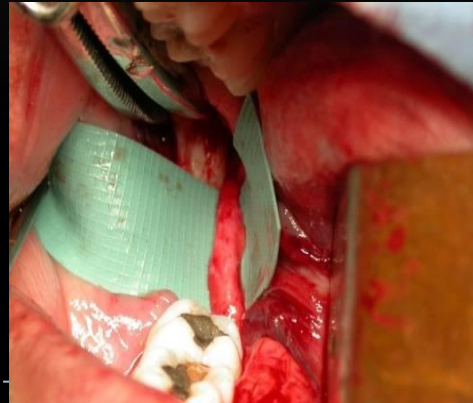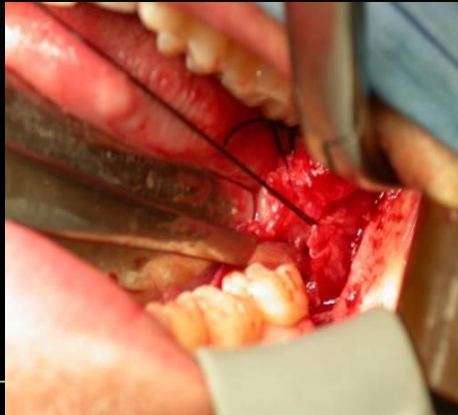
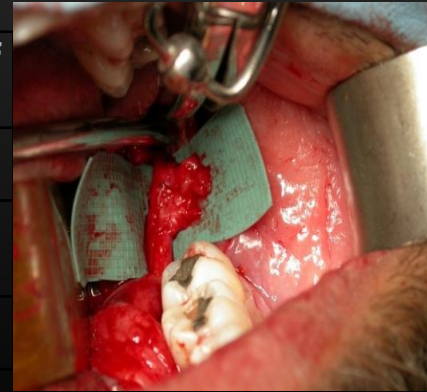Allowing for earlier lingual nerve exploration and repair if necessary

NOT waiting for 12 weeks for resolution associated ONLY with lingual access surgery



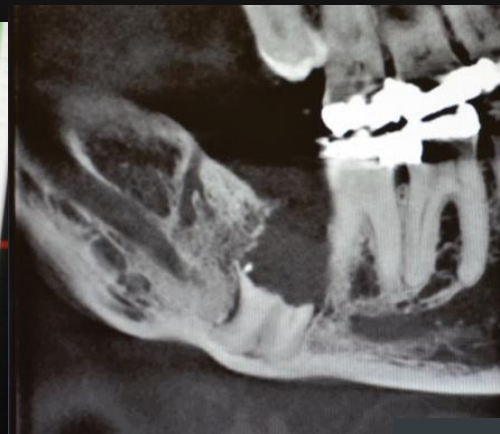
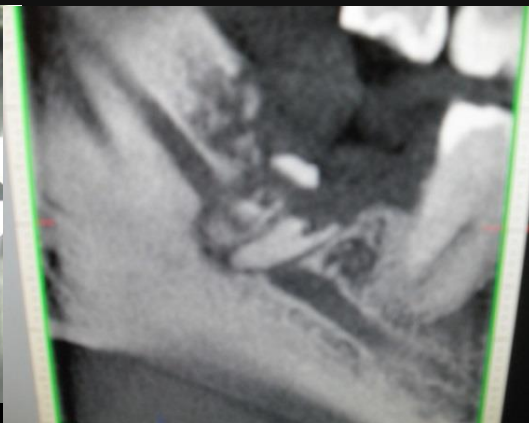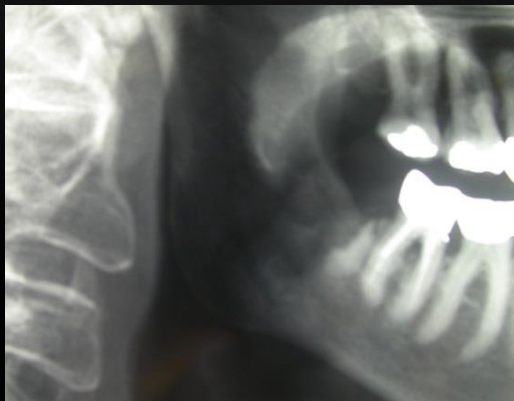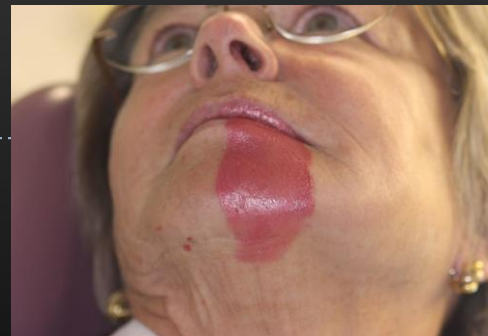Key surgical procedures carried out for LNI patients

Procedure	Number of patients
Exploration and decompression	28
Release of scar tissue, excision of neuroma and re-anastomosis of the nerve	7
Nerve appears normal	1



Early Inferior alveolar nerve surgery

If DPT illustrates retained roots or compressed inferior dental canal (IDC) the CBCT useful to assess root position/ displacement and IDC structure



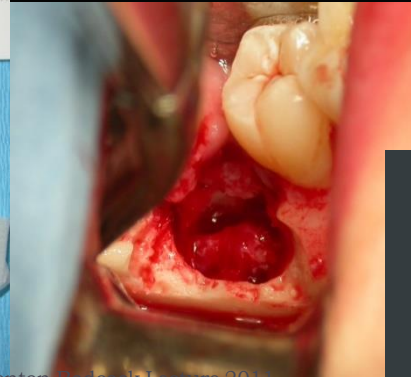
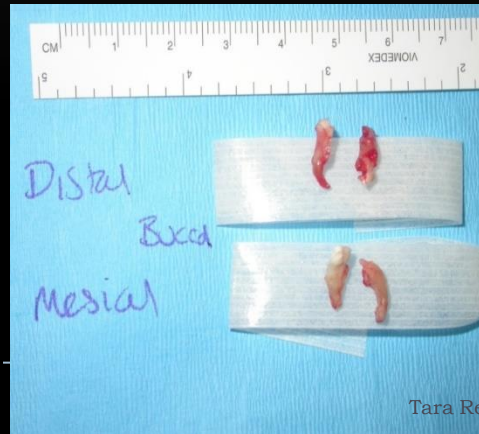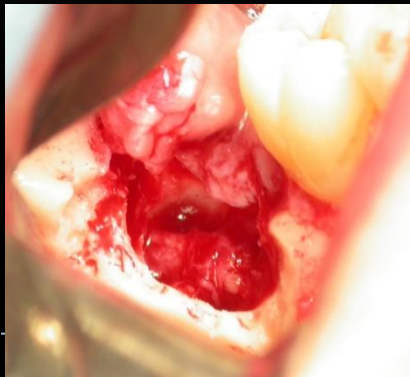
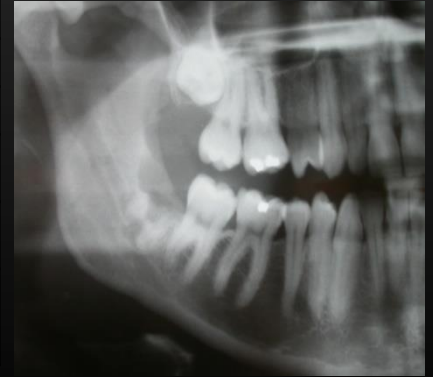A Survey of the Opinion and Experience of UK Dentists: Part 2: Risk Assessment Strategies and the Management of Iatrogenic Trigeminal Nerve Injuries Related to Dental Implant **Surgery**.

Yilmaz Z, Ucer C, Scher E, Suzuki J, Renton T. *Implant Dent.* 2017 Apr;26(2):256-262. doi:

10.1097/ID.0000000000000545

Early surgical intervention for patients IANI

Procedure	Number of patients
Exploration and debridement	1
Exploration and decompression	8
Exploration and removal of roots and decompression	12
Excision of neuroma and reanastomosis of the nerve	3
Extraction of infected retained root and re-anastomosis of the nerve,	1

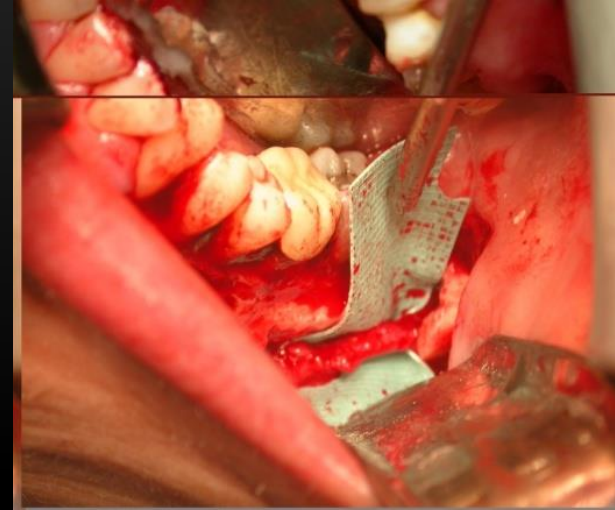


Late management of nerve injury

If injury is > 36 hours days old or more

Manage therapeutically

- Surgery - removal of implant **doesn't work**
- Reassure patient
 - Psychological support
- Pain management **Medical management**
 - Topical Lidocaine patches, Capsaicin, Amitriptyline
 - Systemic Pregabalin / Tricyclic antidepressants



Surgery does NOT 'fix' injuries or resolve pain

Rodriguez-Lozano F, Sanchez-Perez A, Moya-Villaescusa MJ, Rodriguez-Lozano A, Saez-Yuguero MR. Neuropathic orofacial pain after dental implant placement: review of the literature and case report. *OOOE* 2010; **109**: e8-e12. Renton T, Yilmaz Z. Profiling of patients presenting with posttraumatic neuropathy of the trigeminal nerve. *J Orofac Pain*. 2011 Fall;25(4):333-44. Renton T, Dawood A, Shah A, Searson L, Yilmaz Z. Post-implant neuropathy of the trigeminal nerve. A case series. *Br Dent J*. 2012 Jun 8;212(11):E17. doi: 10.1038/sj.bdj.2012.497

Nerve surgery what do we find?

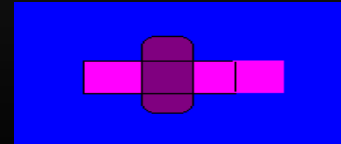
▶ Exploration



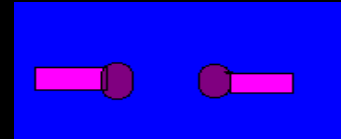
▶ Decompression



▶ Neuroma in continuity (NIC) excision and re-approximation



▶ End neuromata (EN) excision and re-approximation with minimal tension

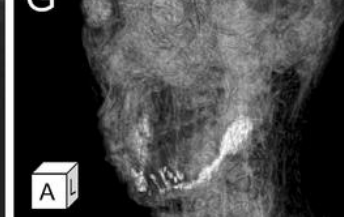
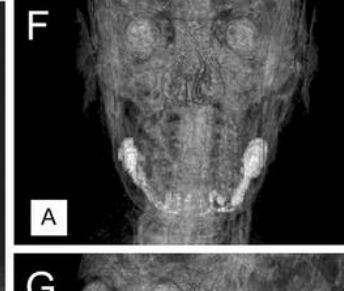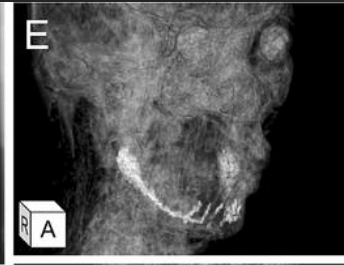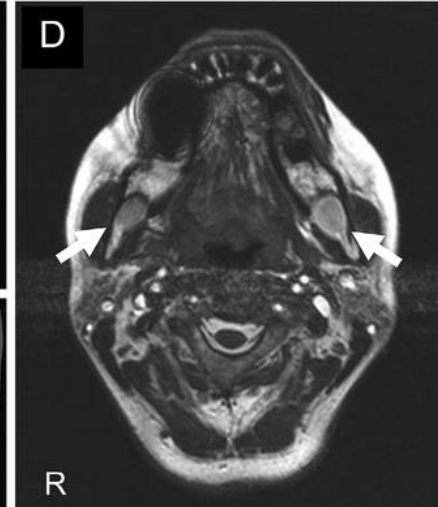
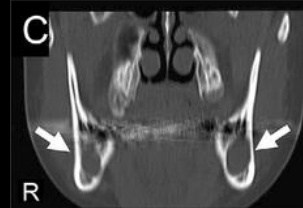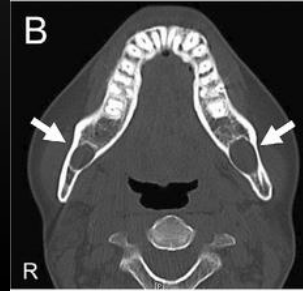
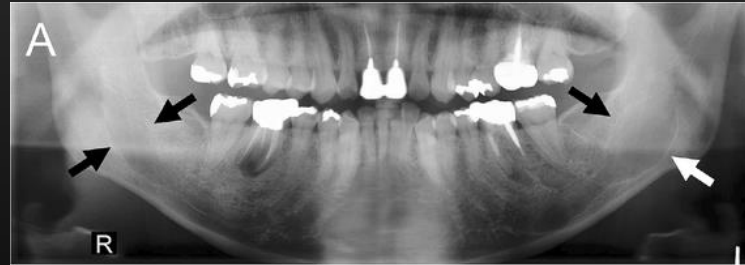


New developments

Zuniga JR, Mistry C, Tikhonov I, Dessouky R, **Chhabra A** Magnetic Resonance Neurography of Traumatic and Nontraumatic Peripheral Trigeminal Neuropathies. J Oral Maxillofac Surg. 2018 Apr;76(4):725-736. doi: 10.1016/j.joms.2017.11.007. Epub 2017 Nov 16.

Dessouky R, Xi Y, **Zuniga J, Chhabra A**. Role of MR Neurography for the Diagnosis of Peripheral Trigeminal Nerve Injuries in Patients with Prior Molar Tooth Extraction. AJNR Am J Neuroradiol. 2018 Jan;39(1):162-169.

Cox B, Zuniga JR, Panchal N, Cheng J, **Chhabra A**. Magnetic resonance neurography in the management of peripheral trigeminal neuropathy: experience in a tertiary care centre. Eur Radiol. 2016 Oct;26(10):3392-400. doi: 10.1007/s00330-015-4182-5. Epub 2016 Jan 21



John Zuniga

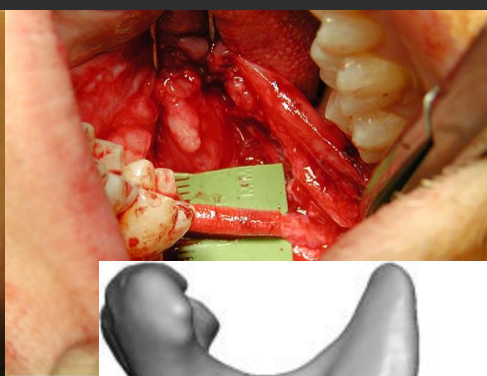
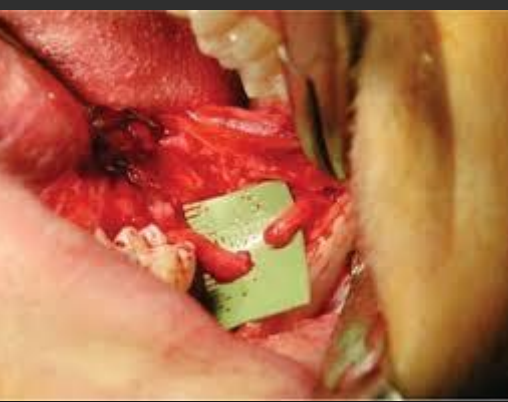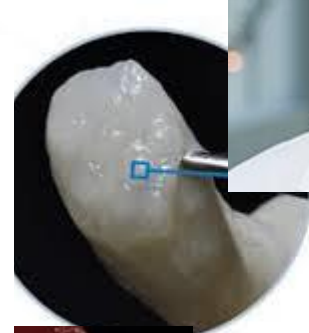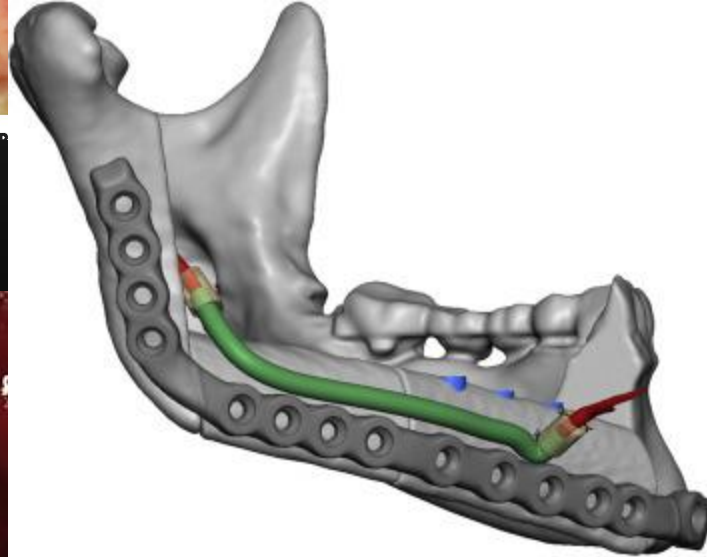


FIGURE 1



Axons grow through multi-tubular structure of Avance® Nerve Graft.

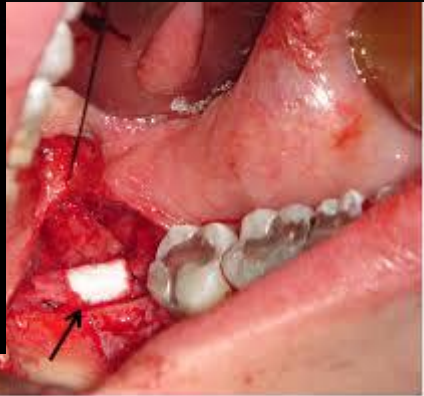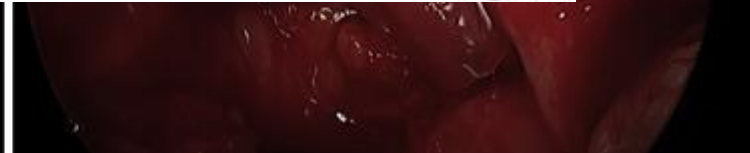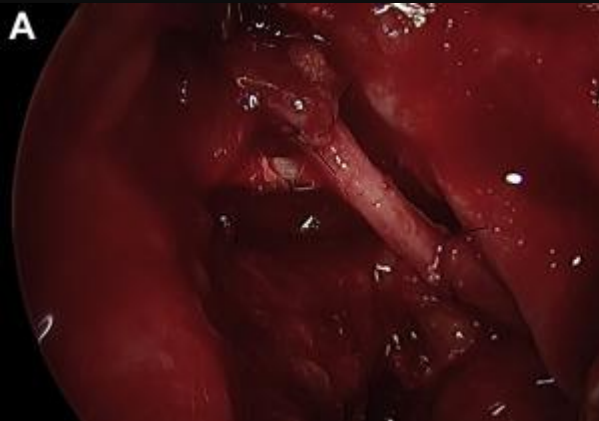


FIGURE 1

Surgical Mx Neuropathic pain

Does NOT respond to late surgery!

ANESTHESIA/FACIAL PAIN

The Presence of Neuropathic Pain Predicts Postoperative Neuropathic Pain Following Trigeminal Nerve Repair

John R. Zuniga, DMD, MS, PbD, David M. Yates, DMD, MD,†
and Ceib L. Phillips, MPH, PbD‡*

Purpose: The risk for the continuation or recurrence of neuropathic pain following trigeminal nerve repair has never been examined. The objective of this study was to determine which risk factors might be associated with the continuation or recurrence of neuropathic pain following trigeminal nerve micro-neurosurgery.

Patients and Methods: An ambispective study design was used to assess subjects who underwent trigeminal nerve repair of the inferior alveolar nerve and lingual nerve between 2000 and 2010. The primary outcome was the presence or absence of neuropathic pain at 3, 6, and 12 months after surgery. Explanatory variables, including age at surgery, gender, presence of neuropathic pain before surgery, site of nerve injury, etiology of nerve injury, classification of nerve injury, duration of nerve injury, and type of repair performed, were abstracted from patient charts. Fisher exact tests were used to compare the demographic and injury characteristics of patients who presented with pain before surgery and those who did not. The McNemar test was used to assess whether there was a significant change in neuropathic pain report from before to after surgery. The level of significance was set at .50.

Results: Of the 65 patients analyzed, two-thirds were women; the average age was 36 ± 16.1 years, and the median time between the injury and surgery was 6.4 months (interquartile range, 6.7 months). Lingual

Conclusions: The presence of neuropathic pain prior to trigeminal micro-neurosurgery is the major risk factor for the continuation or recurrence of postoperative neuropathic pain. These findings suggest that trigeminal nerve surgery is not a risk factor for developing neuropathic pain in the absence of neuropathic pain before surgery.

© 2014 American Association of Oral and Maxillofacial Surgeons
J Oral Maxillofac Surg 72:2422-2427, 2014

IASP Neuropathic SIG Recommendations interventional procedures for Ne Pain

Ne pain due to

- ▶ peripheral and central NP conditions
- ▶ herpes zoster and postherpetic neuralgia (PHN)
- ▶ painful diabetic and other peripheral neuropathies
- ▶ spinal cord injury NP
- ▶ central post-stroke pain
- ▶ radiculopathy
- ▶ failed back surgery syndrome (FBSS)
- ▶ complex regional pain syndrome (CRPS)
- ▶ trigeminal neuralgia and neuropathy

Evidence is summarized and presented for

- ▶ neural blockade,
- ▶ spinal cord stimulation (SCS),
- ▶ intrathecal medication,
- ▶ and neurosurgical interventions

evidence, including degree of efficacy and safety, are: (1) epidural injections for herpes zoster; (2) steroid injections for radiculopathy; (3) SCS for FBSS; and (4) SCS for CRPS type I. Based on the available data, we recommend not to use sympathetic blocks for PHN nor RF lesions for radiculopathy.



HHS Public Access

Author manuscript
Pain. Author manuscript; available in PMC 2015 June 29.

Published in final edited form as:
Pain. 2015 November ; 154(11): 2249–2261. doi:10.1016/j.pain.2015.06.004.

Interventional management of neuropathic pain: NeuPSIG recommendations

Robert H. Dworkin¹, Alec B. O'Connor², Joel Kent³, Sean C. Mackey⁴, Srinivasa N. Rajae⁵,
Brett R. Stacey⁶, Robert M. Levy⁷, Miroslav Backonja⁸, Ralf Baron⁹, Henning Harko¹⁰, John
D. Loeser¹¹, Rolf-Detlef Treede¹², Dennis C. Turk¹³ and Christopher D. Wells¹⁴

¹Departments of Anesthesiology and Neurology and Center for Human Experimental
Therapeutics, University of Rochester School of Medicine and Dentistry, Rochester, NY 14642,
USA

²University of Rochester, Rochester, NY, USA

³Stanford University, Palo Alto, CA, USA

⁴Johns Hopkins University, Baltimore, MD, USA

⁵Oregon Health and Science University, Portland, OR, USA

⁶Northwestern University, Chicago, IL, USA

⁷University of Wisconsin, Madison, WI, USA

⁸University of Kiel, Kiel, Germany

⁹Schmerzfachpraxis, Krefeld, Germany

¹⁰University of Washington, Seattle, WA, USA

¹¹Universität Heidelberg, Mannheim, Germany

¹²Pain Matters, Liverpool, United Kingdom

Corresponding author: Tel.: +1 585 273 8214; fax: +1 585 276-0122; robert_dworkin@uconn.rochester.edu (R.H. Dworkin).

Financial Disclosures: Support for the consensus meeting on which this article is based was provided by the IASP Neuropathic Pain Special Interest Group and by the Neuropathic Pain Institute, which received unrestricted support for their activities from pharmaceutical companies. All authors received an honorarium for participation in the consensus meeting from the University of Rochester Office of Professional Education. RHD has received in the past 12 months research grants from US Food and Drug Administration and US National Institutes of Health, and compensation for activities involving clinical trial research methods from AdvaCare, Analgesic Solutions, Anika, Avast, Axsome, Bayer, Biogen, Biogen, Bristol-Myers Squibb, Charleston, Colgate, Deyco, Fluon, Genentech, Johnson & Johnson, Otsuka, Pfizer, Prion, QMED, Regeneron, Sanofi, SpineRx, Takeda, Tera, Tera, Tera, and Xencor. ABO has no financial disclosures to report. JK has received research support from GlaxoSmithKline and honoraria from Medtronic. SM has received no received research support in the past 12 months from the US National Institutes of Health. SNR has received research support or consulting fees, or honoraria in the past year from Abbott, Aplysin, Schering-Plough, Medtronic, Pfizer, and OTC Pharma. BSJ has received research support, consulting fees, or honoraria in the past year from Abbott, Astra Zeneca, Cadence, Celgene, GlaxoSmithKline, Lilly, Nektar, OTC Pharma, Pfizer, BMS. H has received research support, consulting fees, or honoraria in the past year from Biogen, Codman, Medtronic Neurological, Northstar Neuroscience, St. Jude Neurosciences, and Bristol-Myers Squibb. MB has received research support, consulting fees, or honoraria in the past year from Abbott, Baxo, Genentech, Johnson & Johnson, Lilly, Medtronic, Merck, NeuroRx, and UCB Pharma. RB is a member of the Innovative Medicines Initiative Europan and has received research support, consulting fees, or honoraria from Allergan, Amgen, AstraZeneca, Biogen, Biologics Ingelheim, Bristol-Myers Squibb, Daiichi, Eisai, Genzyme, Genentech, Lilly, Medtronic, Mundipharma, Novartis, Pfizer, Sanofi-Pasteur, Schwarz, Tera, and UCB Biociences. ZL has received consulting fees in the past year from Biologics Sciences, Johnson & Johnson, Medtronic, and Novartis. RDT has received research support, consulting fees, or honoraria in the past year from AVID Pharma, Biologics Ingelheim, Dr. Kade, GlaxoSmithKline, Genentech, and Pfizer. DCT has received research support, consulting fees, or honoraria in the past year from Eisai, Teva, OTC, Lilly, Ortho-McNeil-Janssen, and Tera.

Author Manuscript

Author Manuscript

Author Manuscript

Author Manuscript

Neuropathic pain (NP) is often refractory to pharmacologic and non-interventional treatment. On behalf of the International Association for the Study of Pain Neuropathic Pain Special Interest Group (NeuPSIG),

Other surgical interventions for neuropathic pain

- ▶ **Peripheral stimulation**
 - ▶ Superficial sessional neurostimulation
- ▶ **Central Neurostimulation/ neuromodulation**
 - ▶ SPG - Ganglia implanted neurostimulation
 - ▶ TG Pulsed Radiofrequency
 - ▶ Spinal cord stimulation (not for OFP)
 - ▶ Deep brain stimulation
 - ▶ Transmagnetic stimulation

ABLATIVE TECHNIQUES

Gasserian Ganglion interventions

Radiofrequency ablation

Thermocoagulation

Balloon compression

Glycerolysis

Cryosurgery

Sphenopalatine ganglion injections

Stereotactic radiosurgery

Gamma knife may be indicated if there is medical contraindications to MVD

No evidence in Trigeminal system for PPTTN

Management principles of patient with PTNP

MANAGEMENT OF TRIGEMINAL NERVE INJURIES RELATED TO DENTAL PROCEDURES

Timeline During surgery Post surgery 2 -6 weeks 12 weeks > 12 weeks

Psychological intervention

Medical intervention

High risk nerve injury/ or patient high risk of developing neuropathic pain consider pre-emptive Amitriptyline or Pregabalin	<p>Reported neuropathy immediate post-surgery</p> <ul style="list-style-type: none"> NSAIDs Ibuprofen 6—mg TDS 5 days (MH permitting) step down Prednisolone 50-10mg over 5 days (exclude known risk of DU and or PU) Vitamin B complex (long term during recovery) 	<p>If required: Psychological support (for PTSD and sleep disorders) and Therapeutic management of neuropathic pain (NICE Guidance Ne Pain in adults)</p> <ul style="list-style-type: none"> Step 1 Amitriptyline or Nortriptyline Adjunctive topical agents (Lidocaine, Capsaicin) Step II Gabapentin or Pregabalin
--	--	---

Surgical intervention

<p>Known or suspected nerve Inferior alveolar or lingual injury</p> <p>Duty of candour inform patient immediately</p> <p>Repair nerve immediately Or refer for immediate repair to a specialist centre</p>	<p>Post Local anaesthesia or orthognathic surgery or trauma</p> <p>Duty of candour inform patient immediately</p> <p>Surgery not indicated</p> <p>Medical and psychological therapies</p>	<p>Post Implant or endodontic surgery</p> <p>Patient presents with nerve injury early postoperatively</p> <p>Confirm extensive dermatome affected, anaesthesia, +/- paraesthesia, +/- neuropathic pain</p> <p>Within 30 hours</p> <p>Remove implant or endodontically treated tooth and reassess patient combined with medical intervention above</p>	<p>Post M3M surgery</p> <p>Patient presents with nerve injury early postoperatively</p> <p>Confirm extensive dermatome affected, anaesthesia, +/- paraesthesia, +/- neuropathic pain</p> <p>Inferior alveolar nerve DPT confirms retained roots or bony defect of IDC</p> <p>Lingual nerve (buccal approach) DPT confirms retained roots CBCT confirms lingual plate defect due to M3M surgery</p> <p>Consider early exploration (IAN via M3M socket) +/- nerve repair dependent upon surgical findings</p>	<p>Patient presents with persistent non-resolving LINGUAL nerve injury after lingual access (lingual retraction +/- lingual split) surgery</p> <p>Confirm extensive dermatome affected, anaesthesia, +/- paraesthesia, +/- neuropathic pain</p> <p>Consider exploration @ 12 weeks +/- nerve repair dependent upon surgical findings</p>	<p>Patient presents with persistent non-resolving Inferior alveolar nerve injury OR LINGUAL nerve injury after M3M surgery</p> <p>Confirm extensive dermatome affected, anaesthesia, +/- paraesthesia, +/- neuropathic pain</p> <p>Consider medical and psychological therapeutic measures.</p> <p>N.B Surgical repair DOES NOT IMPROVE neuropathic pain</p>
--	--	---	--	--	---

- *New developments*
- *MRI micro neurography may assist in confirmation of damage to IAN and LN (currently available in US under development London, Belgium).*
- *Larger IAN defects can be optimally repaired using Axogen cadaveric nerve graft (currently NICE approved for hand surgery in UK)*

Key messages...

Prevention of implant related nerve injuries is essential and possible

Good planning and risk assessment

Good surgical technique

Awareness of intraoperative risk factors

Manage the patients expectations

We cannot 'fix' most of these patients with nerve injuries

We can improve informed consent –

Hyperaesthesia and pain are more likely than numbness

Lingual nerve / inferior alveolar nerve injuries are NOT mainly temporary?

DO NOT SIT AND WAIT for resolution

Home check will facilitate timely urgent intervention

Refer to resources at Trigeminalnerve.org.uk

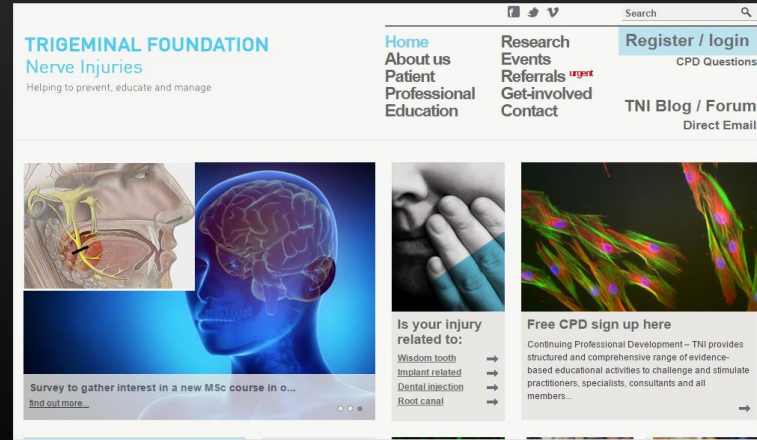


Thank you



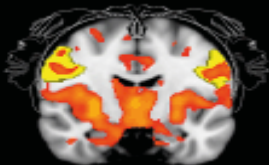
© LaughingStock International Inc., Dist. by Universal Uclick for UFS, 2013.

“Root canal? You’ve charged me for the Suez Canal.”



Websites

Trigeminalnerve.org.uk
Orofacialpain.org.uk



OROFACIAL PAIN MSc

King's College Hospital
NHS Trust



time master's programme

KING'S
College
LONDON

Thank you

kcl.ac.uk/dental-postgraduate

kcl.ac.uk/distancedentistry

KING'S
College
LONDON



[/KingsDentistry](https://www.facebook.com/KingsDentistry)



[@KingsDentistry](https://twitter.com/KingsDentistry)



[/KingsDentistry](https://www.youtube.com/KingsDentistry)



dental-postgraduate@kcl.ac.uk
distancedentistry@kcl.ac.uk



www.kcl.ac.uk/dental-postgraduate
www.kcl.ac.uk/distancedentistry